

Mesenchymal Stem Cells for Regeneration of Cartilage Lesions:

Focus on knee osteoarthritis

Baldur Kristjánsson, MS¹, Thomas Mabey, BS¹, Pongsak Yuktanandana, MD²,

Vinai Parkpian, MD², Sittisak Honsawek, MD^{1,2}

¹*Department of Biochemistry, Faculty of Medicine, Chulalongkorn University,
King Chulalongkorn Memorial Hospital, Thai Red Cross Society, Bangkok, Thailand*

²*Department of Orthopaedics, Faculty of Medicine, Chulalongkorn University,
King Chulalongkorn Memorial Hospital, Thai Red Cross Society, Bangkok, Thailand*

With an increase in life expectancy which causes an ageing population, osteoarthritis, including cartilage loss and other cartilage lesions can become a major health problem. Cartilage has little self-renewal or regeneration capacity and those with cartilage lesions suffer from slow degeneration of the cartilage resulting in pain and loss of function. Conventional treatment for cartilage lesions often results in little or no pain relief leaving major surgery as the only viable option for improving the quality of life. Even so, available surgeries are not a permanent relief of the condition nor do they reverse the process of cartilage degeneration. Limited research funding, low public attention and a poor understanding of the mechanisms behind the conditions are several reasons that contribute to the lack of progress in developing treatments for cartilage degenerative conditions. In addition, cartilage degeneration is usually a slow process and early detection is often difficult due to the lack of biomarkers. In recent years, new methods have been suggested such as the use of autologous mesenchymal stem cells as a treatment of conditions like osteoarthritis. Clinical trials in both animal and human models have shown good results suggesting a simple, effective and lasting solution for cartilage lesions might be around the corner.

The Thai Journal of Orthopaedic Surgery: 37 No.2-4: 67-78

Full text. e journal: <http://www.rcost.or.th>, <http://thailand.digitaljournals.org/index.php/JRCOST>

Introduction

Osteoarthritis (OA) is a pathologic process of degenerative joint disease affecting all joints, though most commonly occurring in the hand, knee, and hip⁽¹⁾. It is the most prevalent chronic joint disease with knee OA being a common form with a high prevalence in Asian countries⁽²⁾. Characteristics of the condition are damage to the articular cartilage, changes in the subchondral bone and synovium, followed by damage to the underlying bone and morphological changes such as subchondral sclerosis, subchondral bone cysts, osteophyte formation and synovitis⁽³⁻⁵⁾. Risk factors for osteoarthritis include a genetic predisposition, hereditary factors, obesity, age, mechanical injury, joint trauma, gender, joint immobilization, and overuse of the joint^(6,7). OA does not only cause disability but has been linked with other conditions

such as neuropathic pain, depression, and sleep disorders⁽⁸⁾. Therefore, it has a great impact on society and is an economic burden responsible for up to 2% of all public health expenses^(9,10). Although OA is a common disease, no approved medical treatment exists to improve or reverse the articular cartilage damage⁽¹¹⁾. Some controversial medications that suppress interleukin 1 and metalloproteinase, and stimulate transforming growth factor- β (TGF- β) may stop or reverse the process but have not been approved as a medical treatment yet. Frequently used treatments include physical therapy⁽¹²⁾, pain control with steroidal and non-steroidal anti-inflammatory drugs, viscosupplementation with injections of sodium hyaluronan as well as a variety of nutraceuticals⁽¹³⁾, however, none of these treatments have an impact on the progression of the condition. Although cell therapy by surgically implanting autologous chondrocytes has been used to regenerate cartilage damage for over two decades, the repair process is slow and often insufficient due to the poor self-renewal and regeneration abilities of the chondrocytes^(14,15). Therefore, the only treatment

*Correspondence to: Honsawek S, Department of Biochemistry and Orthopaedics, Faculty of Medicine, Chulalongkorn University and King Chulalongkorn Memorial Hospital, Thai Red Cross Society, Rama IV road, Patumwan, Bangkok, 10330, Thailand
E-mail: sittisak.h@chula.ac.th*

resulting in a quick relief of the condition is total joint replacement⁽¹³⁾. Total joint replacement is a major surgical procedure with risks of infections as well as the costs of hospital care, physiotherapy and rehabilitation⁽¹⁶⁾; it is therefore only used as a method of last resort. Other less invasive and cheaper methods have been suggested such as the use of stem cells. Mesenchymal stem cells have shown chondrogenic potential *in vitro* and might therefore provide an alternative treatment of damaged cartilage⁽¹⁷⁻¹⁹⁾.

Mesenchymal stem cells

Mesenchymal stem cells (MSCs) are pluripotent progenitor cells. They are capable of establishing colonies from a single cell referred to as colony-forming fibroblast units. They were first described by Alexander Friedenstein as progenitor cells of bone and cartilage in 1966⁽²⁰⁾. Since then they have been shown to have the capacity to differentiate into a variety of cell types including osteoblasts, chondrocytes, adipocytes, and myocytes⁽²¹⁾. They have also been shown to differentiate into nerve cells and hepatocytes which are normally derived from the other two major embryonic germ layers; the ectoderm and endoderm^(22,23). This is known as transdifferentiation or plasticity and MSCs can be considered as a source for more than just mesenchymal tissues^(24,25). MSCs are involved in the maintenance and regeneration of connective tissue and are known to migrate to tissues as a result of inflammation or injury where they participate in the repair of damage^(26,27). They are immunoprivileged cells with immunosuppressive properties⁽²⁸⁾. In addition, MSCs are known to produce a number of secreted factors for example cytokines, chemokines, and growth factors⁽²⁹⁻³¹⁾. MSCs therefore have considerable potential for tissue engineering.

Unlike the highly controversial embryonic stem cells, the MSCs are adult stem cells. They can be found in many tissues and organs but reside mainly within the bone-marrow. Bone-marrow derived mesenchymal stem cells (BMSCs) are therefore a widely used and well-studied cell line. Other common sources include adipose tissues, skeletal muscles, umbilical cord blood and Wharton's Jelly⁽³²⁻³⁴⁾. All of which have the capacity of differentiating into the cell lineages previously mentioned with BMSCs additionally being able to provide the stromal support system for haematopoietic stem cells⁽³⁵⁾. Due to the abundance and distribution of MSCs in adult tissue, a patient's own MSCs can be isolated, expanded, and used as an autologous cell line. Not only does it eliminate the risk of host rejection but also the ethical concerns since the use of autologous cells is a generally accepted practice. When expanding MSCs *in vitro*, they are allowed to pass through

stages known as "passage". Cells are usually let through 2-5 passages but it is not recommended that they pass through 10 or more due to the risk of mutations and tumor genetic effects. Indeed, one of the disadvantages of MSCs is their potential to give rise to or support tumors. In the literature, there exists controversial information with reports of tumor growth suppression as well as both increases and decreases in tumor growth.

Transplantations into immunodeficient animals have shown no evidence of tumor formation⁽³⁶⁾. In 2011 Suzuki et al. showed that MSCs can support tumor growth by supporting the growth of the tumor stroma. They observed a significant increase in tumor growth when co-injecting mice with tumor cells and MSCs. However, their results were also controversial since they observed no increased tumor growth when using a different MSC line⁽³⁷⁾. Therefore, the possibility of tumor development cannot be rejected completely when using MSCs.

Mesenchymal stem cells in joints

Synovial MSCs can be found in most tissues of the synovial joints in mammals. In humans they were first described by De Bari et al. when they successfully isolated MSCs from the synovial membrane in 2001⁽³⁸⁾. Since then they have also been found in the meniscus, ligament, fat pad, cartilage and bone marrow of the synovial joints⁽³⁹⁻⁴³⁾. These cells have the capability of self-renewal and differentiation pathways similar to that of the BMSCs. MSCs from synovial fluid exhibit greater clonogenicity and chondrogenic capacity than those from bone marrow. They also show clonal heterogeneity with individual clonal populations exhibiting variable proliferation and differentiation potentials⁽⁴⁴⁾.

Since MSCs can be found in most tissues of the synovial joints it is likely that they must play a role in providing a reservoir of repair cells that can be activated for growth, repair or remodeling. They might also function as immunomodulatory sentinels for reducing inflammation or the activity of T-cells⁽⁴⁵⁾. MSCs found in cartilage appear to lack the ability of functional repair since it is well known that cartilage fails to regenerate following injury. It is possible that MSCs in the cartilage serve a different purpose for example replenishing the surface zone proteoglycan lubricant to minimize friction⁽⁴⁶⁾.

A significantly greater number of MSCs can be recovered from the effected joints of OA or rheumatoid arthritis patients as well as those of ligament injury compared with that from healthy joints. The number of MSCs also increases with the severity of the disease and one hypothesis suggests that they originate in the degrading synovium⁽⁴⁷⁾. In 2002, Murph et al. showed that MSCs from patients with end-stage OA had reduced *in vitro*

proliferation and differentiation potentials. They compared BMSCs from patients who underwent joint replacement surgery and compared them with samples from matched healthy individuals. They observed a significantly reduced yield and proliferation activity with cells having reduced chondrogenic and adipogenic activity and increased osteogenic potentials⁽⁴⁸⁾. It has been shown that these functional deficiencies can be improved with supplementation of the medium with growth factors⁽⁴⁹⁾.

Availability and safety of MSCs

Obtaining cells for tissue engineering can be a major technical issue. It is possible to use allogeneic cells from donors but this is not common clinical practice due to the risk of rejection or disease transmission⁽⁵⁰⁾. The use of autologous cells is considered safe because there is neither an immunological reaction nor the risk of disease transmission. However, using autologous cells also has limitations; availability may be scarce and it is important to select a tissue which results in minimal morbidity for the patient⁽⁵¹⁾. Autologous BMSCs are widely used because they can be easily obtained causing minimum morbidity and can be collected without producing tissue defects⁽⁵²⁾. The yield obtained from bone-marrow can be quite low and cells are usually expanded *in vitro*. The cells are confirmed as MSCs by checking for surface markers commonly found on MSCs such as CD90 and CD105. Another good source for MSCs is adipose tissue. The number of cells that can be harvested from adipose tissue has been estimated to be up to 1,000 times greater than that from bone-marrow making it a good source for stem cells⁽⁵³⁾. Obtaining adipose derived mesenchymal stem cells (AMSCs) is relatively simple with the use of liposuction where fat-pads are the major harvest sites. Like the harvesting of BMSCs, this technique causes minimal morbidity and is considered a safe method. Other sources of MSCs have been suggested but limited availability and difficulties in extraction have made BMSCs the most commonly used source for clinical application with AMSCs being investigated as a new more potent source of cells. Overall, it is hard to determine the safety of using autologous MSCs, although the risks of rejection or disease transfer is almost non-existent, the long-term effects have not yet been fully studied and the risk of tumor formation exists.

MSCs for cartilage repair

Most reports on the use of MSCs to treat cartilage defects focus on the use of BMSCs and a small number investigating AMSCs. Synovium derived mesenchymal stem cells (SMSCs) have been suggested for cartilage repair since some *in vitro* and animal studies have shown SMSCs to have a greater chondrogenic potential than

BMSCs^(54,55). So far, there have been no clinical trials for this cell source in humans and harvesting SMSCs requires the use of arthroscopy which is more invasive than obtaining BMSCs⁽⁵⁶⁾.

Shigeyuki Wakitani is a pioneer in the field of cartilage repair using MSCs. In 1998 he and his team transplanted BMSCs to repair articular cartilage which was the first such clinical trial ever reported⁽⁵⁷⁾. They performed this procedure on 40 more patients and published the first comprehensive study on the safety, effectiveness, and long-term effects of MSC transplantations for cartilage repair⁽⁵⁸⁾. Their study was a long-term follow up study which included 41 patients with 45 joints and a follow up time of up to 11 years and 5 months. They harvested BMSCs from the iliac crest and expanded them in culture. The cells were delivered with surgery through a gel-cell composite or with the use of collagen sheets^(57,59). The surgeries were performed between January 1998 and November 2008 and the follow up time varied from 5 to 137 months. Of the 41 patients operated on, they were able to follow up on 31. There were no reports of tumor formation or infections over their follow up period. Therefore, they concluded that the use of BMSCs was an effective and safe way of treating cartilage defects. Although they had a long follow up period, the potential risk of tumor formation from stem cells should not be underestimated. Animal studies showed tumor formation or increased tumor proliferation as a result of introducing MSCs into the animals^(60,61).

Autologous chondrocyte implantation for cartilage repair

Autologous chondrocyte implantation (ACI) has been suggested as a promising method for cartilage repair. Many comparative studies have shown promising results and in 2005 Fu et al. reported a significantly greater improvement in function and pain relieve in patients who received ACI treatment compared to those treated with debridement of cartilage defects in the knee⁽⁶²⁾. MSCs have been shown to differentiate into chondrocytes or prevent cartilage degeneration and have therefore been suggested as an alternative cell source for cartilage repair⁽⁶³⁾. By co-culturing MSCs and chondrocytes, Aung et al. were able to differentiate MSCs into chondrocytes without the use of growth factors and at the same time preventing their hypertrophic differentiation⁽⁶⁴⁾.

In 2010, Nejadnik et al. published a paper comparing the use of autologous BMSCs and autologous chondrocytes for treatment of cartilage defects⁽⁵⁶⁾. The chondrocytes were harvested in surgery from non-weight bearing cartilage tissue and expanded in cultures. The BMSCs were harvested from the iliac crest using needle and likewise expanded in cultures. To confirm their

culture indeed existed of MSCs, they checked for cell surface markers commonly found on MSCs. Cell sheets were produced for both chondrocytes and BMSCs by culturing the cells in the presence of ascorbic acid. For each surgery, at least 4 cells sheets were prepared with a cell density of 2×10^6 cells/cm². After cell harvest and expansion, patients underwent ACI surgery⁽¹⁵⁾ and received either a chondrocyte or BMSC sheet implant of approximately $1-1.5 \times 10^6$ cells. Patients were evaluated preoperatively and at 3, 6, 9, 12, 18 and 24 months after surgery. The results showed that patients treated with either ACI or BMSCs had a significant improvement in their quality of life, however, men's health and sport activity showed a greater improvement than that of women. In the ACI group patients older than 45 years had less significant improvements than younger patients but this was not observed in the BMSC group. This study suggests that both treatments are an effective way of relieving pain and improving the quality of life. The advantages of BMSCs treatment are that it requires one fewer surgeries and that the surgery is less invasive resulting in lower morbidity and hospitalization costs. Moreover, treatment with BMSCs showed no difference between age groups.

Bone-marrow derived MSCs in clinical use

The first report of using BMSCs to treat osteoarthritis was documented by Wakitani et al. in 2002⁽⁵⁹⁾. The study consisted of 24 patients with knee osteoarthritis who underwent a high tibial osteotomy. Twelve of these patients received autologous BMSC transplantations and the other 12 served as a control group. BMSCs were harvested from the iliac crest and expanded in cultures. During the high tibial osteotomy, the knee joint was opened using the parapatellar medial approach. They observed the medial femoral condyle and medial tibial plateau; in all cases the articular cartilage on the medial femoral condyle was lost as well as the sub-condral bone being eburnated. The mean number of 1.3×10^7 BMSCs was introduced in a gel-cell composite consisting of 2 ml of 0.25% type I acid soluble collagen from the porcine tendon put onto a collagen sheet and gelatin. This gel-cell composite was applied to the abraded area and covered with collagen sheets. They were able to obtain samples of repair tissue and observe the transplants through arthroscopy in the following two surgeries when the pins and staples were removed. Clinical evaluations before and after surgeries were performed using the Hospital for Special Surgery knee-rating scale. Both groups showed significant improvements in pain, function and muscle strength. However, no difference was observed between the cell-transplanted group and cell-free group. Interestingly, it was observed that, the defects were covered with white soft tissue and some hyaline cartilage-like tissue in the cell-

transplanted group. This was not the case for the cell-free group where white material with an irregular surface could be evident and in some areas underlying bone was visible. Although patients showed no improvement in the quality of life in either group, BMSCs seemed to be able to produce cartilage-like tissue in *in vivo* transplants.

Similar results were reported in 2007 by Kuroda et al. in a 31-year-old patient suffering from pain in the right knee⁽⁶⁵⁾. BMSCs expanded in culture were introduced in a gel-cell composite through surgery. Seven months later arthroscopy revealed the defects to be covered with smooth tissue. Histological staining of samples showed hyaline-like type cartilage tissue that stained positively with Safranin-O. Twelve months after surgery magnetic resonance images (MRI) showed an increased thickness of the cartilage and that the bone was no longer edematous. The patient retained his previous activity level experiencing no pain or complications. These findings suggest that a transplant of autologous BMSCs can promote the repair of large focal articular cartilage defects. However, these studies showed promising results in cartilage repair by introducing cells through a major surgical operation. Since then, less invasive procedures have been suggested and performed by injecting BMSCs or AMSCs directly into the synovium of the knee joint or by performing subchondral microdrilling combined with an injection of growth factors or substances such as hyaluronic acid which has been proved as being beneficial for cartilage health and repair^(66,67).

In 2011, Saw et al. investigated the quality of articular cartilage regeneration after arthroscopic subchondral drilling⁽⁶⁸⁾. They postoperatively injected five patients with autologous peripheral blood progenitor cells (PBPCs) in combination with hyaluronic acid (HA) for improving the regeneration of cartilage. The patients received the first injection one week after the surgery followed by four more injections at weekly intervals. They performed a second-look arthroscopy which confirmed articular cartilage regeneration and histologic sections stained positive suggesting the formation of hyaline cartilage, both of which are consistent results with previous findings. In addition, they also performed histologic and MRI studies of articular cartilage regeneration in patients treated with or without PBPCs and HA after arthroscopic subchondral drilling⁽⁶⁹⁾. The intervention group's histologic scores and MRI scores were significantly better than those of the control group. It was concluded that treatment by regularly injecting PBPCs and HA after surgery improved the quality of articular cartilage repair. Studies on the effects of direct injection of MSCs without any surgical procedures have also shown promising results in the treatment of knee osteoarthritis (Fig. 1).

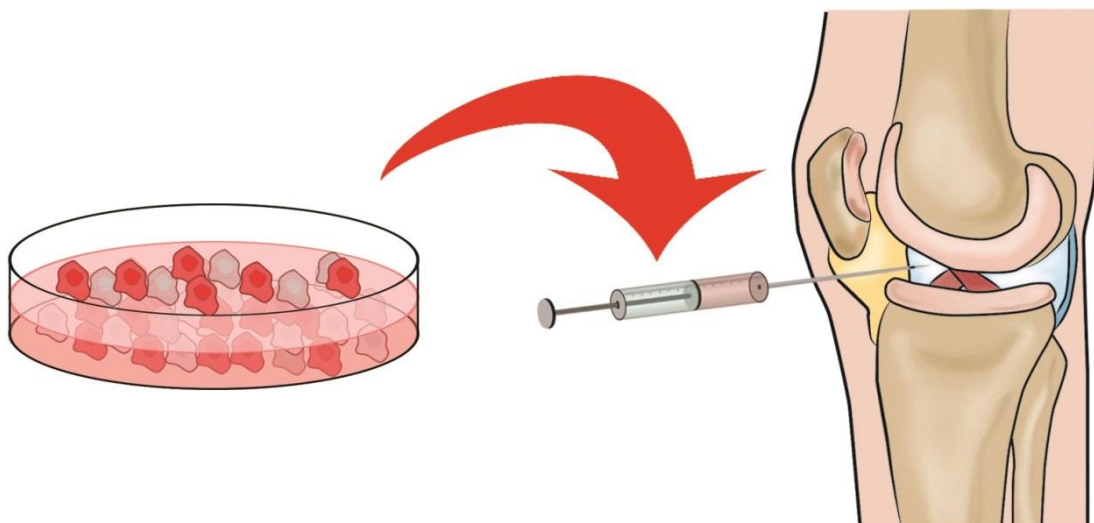


Fig. 1 Direct intra-articular injection of mesenchymal stem cells. Mesenchymal stem cells are harvested from various sites, most commonly bone-marrow or adipose tissues. They can be expanded in culture and then injected in suspension directly into the patients' knee.

Bone-marrow derived MSCs in the treatment of osteoarthritis

In 2011, Davatchi et al. reported their results on the direct injection of BMSCs into the knees of patients suffering from osteoarthritis⁽⁷⁰⁾. All four patients in this study were over 50 years old and suffering from moderate to severe knee osteoarthritis due to obesity. BMSCs were obtained from 30 ml of bone-marrow blood from the patients and expanded in culture; they were confirmed as MSCs by immunophenotyping. The mean volume of 5.5 ml containing $8-9 \times 10^6$ cells was injected into one knee of each patient. Although improvement was observed in 3 out of 4 patient it was minor and the researcher concluded the results as encouraging, but not excellent. Another similar report from 2012 describes 6 female volunteers who needed total joint replacement (TJR) surgery but received a BMSCs injection instead⁽⁷¹⁾. In this study the obtained 50 ml of bone-marrow blood and expanded in culture, likewise they confirmed their cell population as MSCs by immunophenotyping. They injected $20-24 \times 10^6$ BMSCs intra-articularly into the knees of the volunteers. MRI demonstrated an increased cartilage thickness in 3 out of 6 patients and patients reported a reduction of pain as well as improvement in walking distance for the first 6 months then slightly reducing for the following 6 months. Taken together, these studies were both promising and encouraging but not fully satisfactory as a standard treatment for knee osteoarthritis.

More promising results with intra-articular injections of autologous BMSCs alone were produced in 2013 by Orozco et al.⁽⁷²⁾. Their study consisted of 12 patients with osteoarthritic knee

pain who failed conservative treatment and 9 out of 12 had already undergone previous surgery. Bone-marrow was extracted from the iliac crest for MSC isolation. Cells were expanded in culture and confirmed as MSCs by immunophenotyping. After 3 weeks of cell culture, cells were harvested and injected into the patients. The patients received an 8 ml of 40×10^6 cells injection which was considerably larger number than in previous comparable studies^(70,71). Clinical outcomes were followed for one year by evaluating pain, disability, quality of life as well as measuring articular cartilage quality through MRI. By 3 months, pain was significantly reduced with additional progress in the 9 months to follow and was significant at all-time points observed. Patients showed rapid and progressive improvement of the Lequesne index that approached 65-78% after 1 year. Patients were also satisfied with the treatment and 11 out of 12 reported lasting pain relief throughout the study period. MRI also showed a significant increase and improvement in cartilage quantity and quality in 11 out of 12 patients. Furthermore, it was demonstrated that the feasibility and safety of the treatment reached up to 78% of treatment results with 100% being a perfect treatment. It compared favorably with the conventional treatments producing considerably better results. Additionally, it compares well with other invasive methods such as TJR surgery since it is simple and does not require hospitalization or surgery, resulting in overall lower costs. Their results were considerably better than in the similar studies mentioned previously. One of the reasons might be that they injected approximately 2-4 times more MSCs than in the other two studies.

Adipose derived MSCs (AMSCs) as treatment for osteoarthritis

Although the main focus has been on the use of BMSCs, some researchers have chosen to use AMSCs as an alternative tissue. This is due to the abundance of available adipose tissue for cell harvesting and the higher yield obtained from each gram of tissue. In 2012 and 2013, Koh et al. published two papers on the same study which revolved around the use of AMSCs for the treatment of osteoarthritis^(73, 74). This study recruited 18 patients who received an injection of AMSCs to the knee. The adipose tissue was harvested from the inner side of the infrapatellar fat pad via a skin incision after arthroscopic debridement. Interestingly, they did not culture the cells but directly isolated them from the fat tissue by centrifuging the tissue sample. They did not perform immunophenotyping to confirm their cell population as MSCs, but simply counted them with a hemocytometer and presumed their cell population consisted of MSCs. Since this was a quick process, they were able to inject the cells back into the patients on the same day as they were harvested. They did not receive the same yield of cells from each patient and the injected cells ranged from 0.3×10^6 to 2.7×10^6 in number. Clinical outcomes were evaluated before treatment and in the following two years after treatment. Overall, the treatment was a success and there was no major complication. The data showed a significant reduction of pain and an increased quality of life for all patients. A positive correlation was found between the number of cells injected and pain improvement. Furthermore, MRI images taken before and after treatment confirmed that the whole-organ MRI score had increased significantly and the improvement was also correlated with the number of cells injected. They concluded that AMSCs were a valid cell source for treating cartilage damage. Their method is also simple and cost effective with cells being harvested and re-injected into the patient on the same day resulting in reduced costs from cell expansion and from the fact that no hospitalization is required. The weakness of their study was that they did not confirm their population as MSCs. Therefore, the cell population might consist of more cell types such as adipocytes. They also noted that the number of AMSCs that can be isolated for the infrapatellar fat pad is limited and a source that could provide a higher yield of stem cells would be preferable. The fact that they observed greater improvements in patients who received higher numbers of cells in their injections is consistent with the studies previously mentioned. Davatchi et al. injected $8-9 \times 10^6$ cells observing minimal improvement, Emadedin et al. injected $20-24 \times 10^6$ with promising results but not satisfactory while Orozco et al. injected 40×10^6 cells producing satisfactory and

good results both in the quality of life for patients and articular cartilage regeneration⁽⁷⁰⁻⁷²⁾. The effectiveness of intra-articular delivery of MSCs in the knee has already been investigated in a number of clinical trials (Table 1).

Current clinical trials

Currently, a number of clinical trials are underway in the treatment of cartilage damage with MSCs. Out of the 13 clinical trials listed in the National Library of Medicine on the clinicaltrials.gov website in 2012, 11 are focused on the treatment of knee osteoarthritis⁽⁴⁵⁾. They mainly revolve around the use of expanded autologous MSCs derived either from bone-marrow or adipose tissue, although some trials use allogenic or non-culture expanded MSCs. Most researchers focus on the use of intra-articular injections without the use of scaffolds or major surgeries since injections are more cost effective, cause little morbidity and are a desirable way of treatment if they are successful. Since optimal dose-studies have not been carried out yet the ideal dose of MSCs is unknown and doses in the current trials ranges from 1×10^7 to 1×10^8 . These studies will further help in determining what tissues are good sources of viable MSCs for cartilage repair, what the optimal dose-size should be as well as demonstrating if a single injection is sufficient or multiple injections might be required for satisfying results.

Conclusion

The promising results from the studies described in this review show that there are alternative ways to treat moderate to late stage OA. The traditional major surgeries used to treat the condition are both expensive and come with risks. The less invasive methods described here have shown good results but the development of the treatment is ongoing. Better results were obtained with higher numbers of MSCs injected but the optimum dose still remains to be decided. Interestingly, no studies used multiple injections but instead all focused on a single injection hoping it would provide permanent relief of the condition. The results from the single injection studies showed that there was an improvement, but in some cases that improvement was reduced over time. Multiple or even regular injections of MSCs into the joints might be necessary. The dream solution would be a single injection of MSCs alone or in combination of growth factors, which would fully regenerate articular cartilage damage and result in a lasting tissue and eliminating the pain which follows the condition. In order to achieve such a dream solution, a number of studies are needed with satisfying and consistent results as well as determining all factors of the treatment such as dose-size, vehicles used to deliver and if any external factors are needed.

Table 1 Summary of studies where MSCs were used for treating articular cartilage damage in the knee joints

Study	Number of patients	Delivery system	Number of cells	Follow-up time	Control group	MSCs cell origin	Defects
Safety of autologous bone marrow-derived mesenchymal stem cell transplantation for cartilage repair in 41 patients with 45 joints followed for up to 11 years and 5 months ⁽⁵⁸⁾	41	Surgery, implantation, cell sheets, gel-cell composite	N/A	5-137 months	None	Autologous BMSCs from iliac crest	Various cartilage defects (not including osteoarthritis)
Autologous bone marrow derived mesenchymal stem cells versus autologous chondrocyte implantation ⁽⁵⁶⁾	36	ACI surgery, implantation cell sheets	$1.0 \times 10^7 - 1.5 \times 10^7$	24 months	36 patients receiving chondrocyte treatment	Autologous BMSCs from iliac crest	Knee cartilage defects (not including osteoarthritis)
Increased knee cartilage volume in degenerative joint disease using percutaneously implanted, autologous mesenchymal stem cells ⁽⁷⁵⁾	1	Three Intra-articular injection	2.24×10^7	3 months	None	Autologous BMSCs from iliac crest	Knee osteoarthritis
Osteochondral lesions of the knee: A new one-step repair technique with bone marrow-derived cells ⁽⁷⁶⁾	20	Surgery, implantation hyaluronic acid membrane scaffold	N/A, 2 ml of bone-marrow concentrate	24 months	None	Autologous BMSCs from iliac crest	Knee cartilage defects (including osteoarthritis)
Regeneration of meniscus cartilage in a knee treated with percutaneously implanted autologous mesenchymal stem cells ⁽⁷⁷⁾	1	Three timely spaced intra-articular injections	4.56×10^7	3 months	None	Autologous BMSCs from posterior superior iliac spine	Knee osteoarthritis
Treatment of a full-thickness articular cartilage defect in the femoral condyle of an athlete with autologous bone marrow stromal cells ⁽⁶⁵⁾	1	Surgery, implantation, gel-cell composite	N/A	12 months	None	Autologous BMSCs from iliac crest	Knee cartilage defect
Mesenchymal stem cell injections improve symptoms of knee osteoarthritis ⁽⁷⁴⁾	18	Single intra-articular injection	1.18×10^6	24 months	None	Autologous AMSCs from infrapatellar fat pad	Knee osteoarthritis
Infrapatellar fat pad-derived mesenchymal stem cell therapy for knee osteoarthritis ⁽⁷³⁾	25	Single intra-articular injection	1.18×10^6	12 months	25 cell free controls	Autologous AMSCs from infrapatellar fat pad	Knee osteoarthritis
Human autologous culture expanded bone marrow mesenchymal cell transplantation for repair of cartilage defects in osteoarthritic knees ⁽⁵⁹⁾	12	Surgery, implantation, cell sheets, gel-cell composite	1.3×10^7	28-95 weeks	12 cell free controls	Autologous BMSCs from iliac crest	Knee osteoarthritis
Intra-articular injection of autologous mesenchymal stem cells in six patients with knee osteoarthritis ⁽⁷¹⁾	6	Single intra-articular injection	$2.0 \times 10^7 - 2.4 \times 10^7$	12 months	None	Autologous BMSCs from iliac crest	Knee osteoarthritis
Mesenchymal stem cell therapy for knee osteoarthritis. Preliminary report of four patients ⁽⁷⁰⁾	4	Single intra-articular injection	$8.0 \times 10^6 - 9.0 \times 10^6$	12 months	None	Autologous BMSCs	Knee osteoarthritis
Treatment of knee osteoarthritis with autologous mesenchymal stem cells: A pilot study ⁽⁷²⁾	12	Single intra-articular injection	4.0×10^7	12 months	None	Autologous BMSCs from iliac crest	Knee osteoarthritis

References

- Buckwalter JA, Martin JA. Osteoarthritis. *Adv Drug Deliv Rev* 2006; 58: 150-67.
- Davatchi F. Rheumatic diseases in the APLAR region. *APLAR Journal of Rheumatology* 2006; 9: 6.
- Findlay DM. If good things come from above, do bad things come from below? *Arthritis Res Ther* 2010; 12: 119.
- Goldring MB, Goldring SR. Articular cartilage and subchondral bone in the pathogenesis of osteoarthritis. *Ann N Y Acad Sci* 2010; 1192: 230-7.
- de Lange-Brokaar BJ, Ioan-Facsinay A, van Osch GJ, Zuurmond AM, Schoones J, Toes RE, et al. Synovial inflammation, immune cells and their cytokines in osteoarthritis: a review. *Osteoarthritis Cartilage* 2012; 20: 1484-99.
- Haq SA, Davatchi F, Dahaghin S, Islam N, Ghose A, Darmawan J, et al. Development of a questionnaire for identification of the risk factors for osteoarthritis of the knees in developing countries. A pilot study in Iran and Bangladesh. *An ILAR-COPCORD phase III study. Int J Rheum Dis* 2010; 13: 203-14.
- Dahaghin S, Tehrani-Banihashemi SA, Faezi ST, Jamshidi AR, Davatchi F. Squatting, sitting on the floor, or cycling: are life-long daily activities risk factors for clinical knee osteoarthritis? Stage III results of a community-based study. *Arthritis Rheum* 2009; 61: 1337-42.
- Gore M, Tai KS, Sadosky A, Leslie D, Stacey BR. Clinical comorbidities, treatment patterns, and direct medical costs of patients with osteoarthritis in usual care: a retrospective claims database analysis. *J Med Econ* 2011; 14: 497-507.
- Le Pen C, Reygrobelle C, Gerentes I. Financial cost of osteoarthritis in France. The "COART" France study. *Joint Bone Spine* 2005; 72: 567-70.
- Hermans J, Koopmanschap MA, Bierma-Zeinstra SM, van Linge JH, Verhaar JA, Reijman M, et al. Productivity costs and medical costs among working patients with knee osteoarthritis. *Arthritis Care Res (Hoboken)* 2012; 64: 853-61.
- Hawker GA, Mian S, Bednis K, Stanaitis I. Osteoarthritis year 2010 in review: non-pharmacologic therapy. *Osteoarthritis Cartilage* 2011; 19: 366-74.
- Pisters MF, Veenhof C, Schellevis FG, De Bakker DH, Dekker J. Long-term effectiveness of exercise therapy in patients with osteoarthritis of the hip or knee: a randomized controlled trial comparing two different physical therapy interventions. *Osteoarthritis Cartilage* 2010; 18: 1019-26.
- Buckwalter JA, Saltzman C, Brown T. The impact of osteoarthritis: implications for research. *Clin Orthop Relat Res* 2004; 427S: S6-15.
- Vasiliadis HS, Wasiak J. Autologous chondrocyte implantation for full thickness articular cartilage defects of the knee. *Cochrane Database Syst Rev* 2010; 10: CD003323.
- Brittberg M, Lindahl A, Nilsson A, Ohlsson C, Isaksson O, Peterson L. Treatment of deep cartilage defects in the knee with autologous chondrocyte transplantation. *N Engl J Med* 1994; 331: 889-95.
- Kurtz S, Ong K, Lau E, Mowat F, Halpern M. Projections of primary and revision hip and knee arthroplasty in the United States from 2005 to 2030. *J Bone Joint Surg Am* 2007; 89: 780-5.
- Pittenger MF, Mackay AM, Beck SC, Jaiswal RK, Douglas R, Mosca JD, et al. Multilineage potential of adult human mesenchymal stem cells. *Science* 1999; 284: 143-7.
- Gupta PK, Das AK, Chullikana A, Majumdar AS. Mesenchymal stem cells for cartilage repair in osteoarthritis. *Stem Cell Res Ther* 2012; 3: 25.
- Yoo JU, Barthel TS, Nishimura K, Solchaga L, Caplan AI, Goldberg VM, et al. The chondrogenic potential of human bone-marrow-derived mesenchymal progenitor cells. *J Bone Joint Surg Am* 1998; 80: 1745-57.
- Friedenstein AJ, Piatetzky S, II, Petrakova KV. Osteogenesis in transplants of bone marrow cells. *J Embryol Exp Morphol* 1966; 16: 381-90.
- Dominici M, Le Blanc K, Mueller I, Slaper-Cortenbach I, Marini F, Krause D, et al. Minimal criteria for defining multipotent mesenchymal stromal cells. The International Society for Cellular Therapy position statement. *Cytotherapy* 2006; 8: 315-7.
- Petersen BE, Bowen WC, Patrene KD, Mars WM, Sullivan AK, Murase N, et al. Bone marrow as a potential source of hepatic oval cells. *Science* 1999; 284: 1168-70.
- Kopen GC, Prockop DJ, Phinney DG. Marrow stromal cells migrate throughout forebrain and cerebellum, and they differentiate into astrocytes after injection into neonatal mouse brains. *Proc Natl Acad Sci U S A* 1999; 96: 10711-6.
- Ma K, Laco F, Ramakrishna S, Liao S, Chan CK. Differentiation of bone marrow-derived mesenchymal stem cells into multi-layered epidermis-like cells in 3D organotypic coculture. *Biomaterials* 2009; 30: 3251-8.
- Dai LJ, Li HY, Guan LX, Ritchie G, Zhou JX. The therapeutic potential of bone marrow-derived mesenchymal stem cells on hepatic cirrhosis. *Stem Cell Res* 2009; 2: 16-25.
- Campagnoli C, Roberts IA, Kumar S, Bennett PR, Bellantuono I, Fisk NM. Identification of

- mesenchymal stem/progenitor cells in human first-trimester fetal blood, liver, and bone marrow. *Blood* 2001; 98: 2396-402.
27. Karp JM, Leng Teo GS. Mesenchymal stem cell homing: the devil is in the details. *Cell Stem Cell* 2009; 4: 206-16.
 28. Uccelli A, Moretta L, Pistoia V. Mesenchymal stem cells in health and disease. *Nat Rev Immunol* 2008; 8: 726-36.
 29. Doorn J, Moll G, Le Blanc K, van Blitterswijk C, de Boer J. Therapeutic applications of mesenchymal stromal cells: paracrine effects and potential improvements. *Tissue Eng Part B Rev* 2012; 18: 101-15.
 30. Meirelles Lda S, Fontes AM, Covas DT, Caplan AI. Mechanisms involved in the therapeutic properties of mesenchymal stem cells. *Cytokine Growth Factor Rev* 2009; 20: 419-27.
 31. Salgado AJ, Reis RL, Sousa NJ, Gimble JM. Adipose tissue derived stem cells secretome: soluble factors and their roles in regenerative medicine. *Curr Stem Cell Res Ther* 2010; 5: 103-10.
 32. Bunnell BA, Estes BT, Guilak F, Gimble JM. Differentiation of adipose stem cells. *Methods Mol Biol* 2008; 456: 155-71.
 33. Crisan M, Yap S, Casteilla L, Chen CW, Corselli M, Park TS, et al. A perivascular origin for mesenchymal stem cells in multiple human organs. *Cell Stem Cell* 2008; 3(3): 301-13.
 34. Troyer DL, Weiss ML. Wharton's jelly-derived cells are a primitive stromal cell population. *Stem Cells* 2008; 26: 591-9.
 35. Sacchetti B, Funari A, Michienzi S, Di Cesare S, Piersanti S, Saggio I, et al. Self-renewing osteoprogenitors in bone marrow sinusoids can organize a hematopoietic microenvironment. *Cell* 2007; 131: 324-36.
 36. Bernardo ME, Zaffaroni N, Novara F, Cometa AM, Avanzini MA, Moretta A, et al. Human bone marrow derived mesenchymal stem cells do not undergo transformation after long-term in vitro culture and do not exhibit telomere maintenance mechanisms. *Cancer Res* 2007; 67: 9142-9.
 37. Suzuki K, Sun R, Origuchi M, Kanehira M, Takahata T, Itoh J, et al. Mesenchymal stromal cells promote tumor growth through the enhancement of neovascularization. *Mol Med* 2011; 17: 579-87.
 38. De Bari C, Dell'Accio F, Tylzanowski P, Luyten FP. Multipotent mesenchymal stem cells from adult human synovial membrane. *Arthritis Rheum* 2001; 44: 1928-42.
 39. Segawa Y, Muneta T, Makino H, Nimura A, Mochizuki T, Ju YJ, et al. Mesenchymal stem cells derived from synovium, meniscus, anterior cruciate ligament, and articular chondrocytes share similar gene expression profiles. *J Orthop Res* 2009; 27: 435-41.
 40. Steinert AF, Kunz M, Prager P, Barthel T, Jakob F, Noth U, et al. Mesenchymal stem cell characteristics of human anterior cruciate ligament outgrowth cells. *Tissue Eng Part A* 2011; 17: 1375-88.
 41. Khan WS, Adesida AB, Tew SR, Longo UG, Hardingham TE. Fat pad-derived mesenchymal stem cells as a potential source for cell-based adipose tissue repair strategies. *Cell Prolif* 2012; 45: 111-20.
 42. Williams R, Khan IM, Richardson K, Nelson L, McCarthy HE, Anabelsi T, et al. Identification and clonal characterisation of a progenitor cell sub-population in normal human articular cartilage. *PLoS One* 2010; 5: e13246.
 43. Barry FP, Murphy JM. Mesenchymal stem cells: clinical applications and biological characterization. *Int J Biochem Cell Biol* 2004; 36: 568-84.
 44. Karystinou A, Dell'Accio F, Kurth TB, Wackerhage H, Khan IM, Archer CW, et al. Distinct mesenchymal progenitor cell subsets in the adult human synovium. *Rheumatology (Oxford)* 2009; 48: 1057-64.
 45. Barry F, Murphy M. Mesenchymal stem cells in joint disease and repair. *Nat Rev Rheumatol* 2013; 9: 584-94.
 46. Flannery CR, Hughes CE, Schumacher BL, Tudor D, Aydelotte MB, Kuettner KE, et al. Articular cartilage superficial zone protein (SZP) is homologous to megakaryocyte stimulating factor precursor and is a multifunctional proteoglycan with potential growth-promoting, cytoprotective, and lubricating properties in cartilage metabolism. *Biochem Biophys Res Commun* 1999; 254: 535-41.
 47. Lee DH, Sonn CH, Han SB, Oh Y, Lee KM, Lee SH. Synovial fluid CD34(-) CD44(+) CD90(+) mesenchymal stem cell levels are associated with the severity of primary knee osteoarthritis. *Osteoarthritis Cartilage* 2012; 20: 106-9.
 48. Murphy JM, Dixon K, Beck S, Fabian D, Feldman A, Barry F. Reduced chondrogenic and adipogenic activity of mesenchymal stem cells from patients with advanced osteoarthritis. *Arthritis Rheum* 2002; 46: 704-13.
 49. Scharstuhl A, Schewe B, Benz K, Gaissmaier C, Buhning HJ, Stoop R. Chondrogenic potential of human adult mesenchymal stem cells is independent of age or osteoarthritis etiology. *Stem Cells* 2007; 25: 3244-51.
 50. Wakitani S, Kimura T, Hirooka A, Ochi T, Yoneda M, Yasui N, et al. Repair of rabbit articular surfaces with allograft chondrocytes embedded in collagen gel. *J Bone Joint Surg Br* 1989; 71: 74-80.
 51. Ochi M, Uchio Y, Kawasaki K, Wakitani S, Iwasa J. Transplantation of cartilage-like tissue

- made by tissue engineering in the treatment of cartilage defects of the knee. *J Bone Joint Surg Br* 2002; 84: 571-8.
52. Wakitani S, Goto T, Pineda SJ, Young RG, Mansour JM, Caplan AI, et al. Mesenchymal cell-based repair of large, full-thickness defects of articular cartilage. *J Bone Joint Surg Am* 1994; 76: 579-92.
 53. Aust L, Devlin B, Foster SJ, Halvorsen YD, Hicok K, du Laney T, et al. Yield of human adipose-derived adult stem cells from liposuction aspirates. *Cytotherapy* 2004; 6: 7-14.
 54. Pei M, He F, Boyce BM, Kish VL. Repair of full-thickness femoral condyle cartilage defects using allogeneic synovial cell-engineered tissue constructs. *Osteoarthritis Cartilage* 2009; 17: 714-22.
 55. Shirasawa S, Sekiya I, Sakaguchi Y, Yagishita K, Ichinose S, Muneta T. In vitro chondrogenesis of human synovium-derived mesenchymal stem cells: optimal condition and comparison with bone marrow-derived cells. *J Cell Biochem* 2006; 97: 84-97.
 56. Nejadnik H, Hui JH, Feng Choong EP, Tai BC, Lee EH. Autologous bone marrow-derived mesenchymal stem cells versus autologous chondrocyte implantation: an observational cohort study. *Am J Sports Med* 2010; 38: 1110-6.
 57. Wakitani S, Mitsuoka T, Nakamura N, Toritsuka Y, Nakamura Y, Horibe S. Autologous bone marrow stromal cell transplantation for repair of full-thickness articular cartilage defects in human patellae: two case reports. *Cell Transplant* 2004; 13: 595-600.
 58. Wakitani S, Okabe T, Horibe S, Mitsuoka T, Saito M, Koyama T, et al. Safety of autologous bone marrow-derived mesenchymal stem cell transplantation for cartilage repair in 41 patients with 45 joints followed for up to 11 years and 5 months. *J Tissue Eng Regen Med* 2011; 5: 146-50.
 59. Wakitani S, Imoto K, Yamamoto T, Saito M, Murata N, Yoneda M. Human autologous culture expanded bone marrow mesenchymal cell transplantation for repair of cartilage defects in osteoarthritic knees. *Osteoarthritis Cartilage* 2002; 10: 199-206.
 60. Karnoub AE, Dash AB, Vo AP, Sullivan A, Brooks MW, Bell GW, et al. Mesenchymal stem cells within tumour stroma promote breast cancer metastasis. *Nature* 2007; 449: 557-63.
 61. Spaeth EL, Dembinski JL, Sasser AK, Watson K, Klopp A, Hall B, et al. Mesenchymal stem cell transition to tumor-associated fibroblasts contributes to fibrovascular network expansion and tumor progression. *PLoS One* 2009; 4: e4992.
 62. Fu FH, Zurakowski D, Browne JE, Mandelbaum B, Erggelet C, Moseley JB, Jr., et al. Autologous chondrocyte implantation versus debridement for treatment of full-thickness chondral defects of the knee: an observational cohort study with 3-year follow-up. *Am J Sports Med* 2005; 33(11): 1658-66.
 63. Vinatier C, Bouffi C, Merceron C, Gordeladze J, Brondello JM, Jorgensen C, et al. Cartilage tissue engineering: towards a biomaterial-assisted mesenchymal stem cell therapy. *Curr Stem Cell Res Ther* 2009; 4: 318-29.
 64. Aung A, Gupta G, Majid G, Varghese S. Osteoarthritic chondrocyte-secreted morphogens induce chondrogenic differentiation of human mesenchymal stem cells. *Arthritis Rheum* 2011; 63: 148-58.
 65. Kuroda R, Ishida K, Matsumoto T, Akisue T, Fujioka H, Mizuno K, et al. Treatment of a full-thickness articular cartilage defect in the femoral condyle of an athlete with autologous bone-marrow stromal cells. *Osteoarthritis Cartilage* 2007; 15: 226-31.
 66. Kaplan LD, Lu Y, Snitzer J, Nemke B, Hao Z, Biro S, et al. The effect of early hyaluronic acid delivery on the development of an acute articular cartilage lesion in a sheep model. *Am J Sports Med* 2009; 37: 2323-7.
 67. Turajane T, Chaweewannakorn U, Larbpaiboonpong V, Aojanepong J, Thitiset T, Honsawek S, et al. Combination of intra-articular autologous activated peripheral blood stem cells with growth factor addition/preservation and hyaluronic acid in conjunction with arthroscopic microdrilling mesenchymal cell stimulation Improves quality of life and regenerates articular cartilage in early osteoarthritic knee disease. *J Med Assoc Thai* 2013; 96: 580-8.
 68. Saw KY, Anz A, Merican S, Tay YG, Ragavanaidu K, Jee CS, et al. Articular cartilage regeneration with autologous peripheral blood progenitor cells and hyaluronic acid after arthroscopic subchondral drilling: a report of 5 cases with histology. *Arthroscopy* 2011; 27: 493-506.
 69. Saw KY, Anz A, Siew-Yoke Jee C, Merican S, Ching-Soong Ng R, Roohi SA, et al. Articular cartilage regeneration with autologous peripheral blood stem cells versus hyaluronic acid: a randomized controlled trial. *Arthroscopy* 2013; 29: 684-94.
 70. Davatchi F, Abdollahi BS, Mohyeddin M, Shahram F, Nikbin B. Mesenchymal stem cell therapy for knee osteoarthritis. Preliminary report of four patients. *Int J Rheum Dis* 2011; 14: 211-5.
 71. Emadedin M, Aghdami N, Taghiyar L, Fazeli R, Moghadasali R, Jahangir S, et al. Intra-articular injection of autologous mesenchymal stem cells

- in six patients with knee osteoarthritis. Arch Iran Med 2012; 15: 422-8.
72. Orozco L, Munar A, Soler R, Alberca M, Soler F, Huguet M, et al. Treatment of knee osteoarthritis with autologous mesenchymal stem cells: a pilot study. Transplantation 2013; 95: 1535-41.
73. Koh YG, Choi YJ. Infrapatellar fat pad-derived mesenchymal stem cell therapy for knee osteoarthritis. Knee 2012; 19: 902-7.
74. Koh YG, Jo SB, Kwon OR, Suh DS, Lee SW, Park SH, et al. Mesenchymal stem cell injections improve symptoms of knee osteoarthritis. Arthroscopy 2013; 29: 748-55.
75. Centeno CJ, Busse D, Kisiday J, Keohan C, Freeman M, Karli D. Increased knee cartilage volume in degenerative joint disease using percutaneously implanted, autologous mesenchymal stem cells. Pain Physician 2008; 11: 343-53.
76. Buda R, Vannini F, Cavallo M, Grigolo B, Cenacchi A, Giannini S. Osteochondral lesions of the knee: a new one-step repair technique with bone-marrow-derived cells. J Bone Joint Surg Am 2010; 92 S2: 2-11.
77. Centeno CJ, Busse D, Kisiday J, Keohan C, Freeman M, Karli D. Regeneration of meniscus cartilage in a knee treated with percutaneously implanted autologous mesenchymal stem cells. Med Hypotheses 2008; 71: 900-8.

เซลล์ต้นกำเนิดมีเซนไคมอลสำหรับการรักษารอยโรคกระดูกอ่อนในโรคข้อเสื่อม

บาลเดอ์ คริสเตียนสัน, โทมัส มาเบย, พงศ์ศักดิ์ ยุกตะนันท์, พบ, วินัย พากเพียร, พบ,
สิทธิศักดิ์ หารรษาเวก, พบ

โรคข้อเสื่อมเป็นโรคที่เกิดพยาธิสภาพภายในข้อ ทำให้มีการสูญเสียกระดูกอ่อนผิวข้อ และเป็นปัญหาที่สำคัญต่อสุขภาพ โดยเฉพาะผู้สูงอายุซึ่งมีจำนวนประชากรเพิ่มขึ้น กระดูกอ่อนมีศักยภาพในการเจริญสร้างทดแทนใหม่ได้จำกัด ดังนั้นรอยโรคกระดูกอ่อนเกิดจากการเสื่อมสภาพของกระดูกอ่อนอย่างช้าที่ละน้อย ทำให้ผู้ป่วยโรคข้อเสื่อมเกิดการเจ็บปวดและสูญเสียการใช้งานของข้อ การรักษารอยโรคกระดูกอ่อนส่วนใหญ่เป็นการรักษาเพื่อบรรเทาอาการเจ็บปวดและการรักษาโดยการผ่าตัด เพื่อเพิ่มคุณภาพชีวิตให้แก่ผู้ป่วย การศึกษาวิจัยโดยให้ความสำคัญและเข้าใจกลไกการเกิดพยาธิสภาพของโรคข้อเสื่อม มีส่วนช่วยในการพัฒนาวิธีการรักษาโรคข้อเสื่อมได้ดีขึ้น

ในปัจจุบันมีการศึกษาวิจัย โดยใช้เซลล์ต้นกำเนิดมีเซนไคมอลในการรักษาโรคข้อเสื่อมมากขึ้น การทดลองทางคลินิกทั้งในสัตว์ทดลองและในมนุษย์ที่ผ่านมา มีหลักฐานพบว่าการใช้เซลล์ต้นกำเนิดอาจเป็นการรักษาที่สามารถทำได้ง่ายและมีประสิทธิภาพในการรักษารอยโรคกระดูกอ่อนและโรคข้อเสื่อม ความคาดหวังดังกล่าวคงไม่ไกลเกินความจริง บทความปริทรรศน์นี้เป็นการสรุปรวบรวมการศึกษาวิจัย โดยการใช้เซลล์ต้นกำเนิดที่สำคัญในการรักษารอยโรคกระดูกอ่อนและโรคข้อเสื่อม
