



“Through and Through” Fluoroscopically Guided Catheter Drainage of Extensive Spinal Epidural Abscess: A Case Report

Terdpong Tanaviriyachai, MD, Patchara Pornsopanakorn, MD

Department of Orthopedic Surgery, Maharat Nakhon Ratchasima Hospital, Nakhon Ratchasima, Thailand

Purpose: We aimed to present a case of spondylodiscitis with extensive spinal epidural abscess (SEA) that was successfully treated using a minimally invasive technique supplemented with fluoroscopically guided catheter drainage and systemic antibiotic therapy.

Methods: A 58-year-old man presented with severe back pain and high-grade fever. He had progressive radiating pain in the lower extremities, followed by sensory deficits in both the lower limbs. Laboratory investigations revealed leukocytosis and high C-reactive protein levels. Magnetic resonance imaging of the thoracic and lumbar regions revealed an extremely large posterior SEA that extends from T6 to S1. As the patient did not respond to intravenous antibiotics alone, he underwent skipped laminectomies with fluoroscopically guided catheter drainage and irrigation.

Results: *Escherichia coli* were detected in purulent material from the abscess. His clinical symptoms were dramatically and immediately relieved after the procedure. The patient achieved complete neurological recovery after six weeks of antibiotic therapy.

Conclusions: We suggest a limited approach to the spine with the use of small radio-opaque catheters, representing an interesting option to effectively drain extensive SEAs with less morbidity than the conventional open extensive surgical drainage.

Keywords: through and through spinal irrigation, fluoroscopically guided catheter drainage, extensive epidural abscess, minimally-invasive surgery for spinal drainage

A spinal epidural abscess (SEA) is a catastrophic infection that expands suppurative infection in the spinal canal between the dura mater and vertebral periosteum⁽¹⁾. The reported rates of SEA ranged from 0.2–2.8 cases per 10,000 hospital admissions^(2,3). When SEA involves more than five vertebral levels, it is known as an extensive type; the estimated mortality rate is approximately

15%⁽⁴⁾. Most patients with SEA have one or more predisposing conditions such as an underlying disease (diabetes mellitus, alcoholism, or infection with human immunodeficiency virus), spinal abnormalities (degenerative joint disease or trauma), history of spinal interventions (surgery, drug injection, or placement of stimulators or catheters), or a potential local or systemic source of infection^(4,5).

Prompt surgical decompression combined with systemic antibiotic therapy remains the treatment of choice for patients with SEA, particularly for those with accompanying neurological deficits. To reduce operative morbidity, multilevel SEAs can be drained through a limited open approach, allowing blind epidural

Article history:

Received: April 17, 2022 Revised: July 13, 2022

Accepted: July 28, 2022

Correspondence to: Terdpong Tanaviriyachai, MD
Department of Orthopedic Surgery, Maharat Nakhon Ratchasima Hospital, Nakhon Ratchasima, Thailand
E-mail: Bomorthokorat@gmail.com

catheter irrigation and aspiration^(6,7). Limited exposure of the spinal canal during SEA surgery offers a greater chance of stability preservation and reduced morbidity, especially in patients with comorbidities^(8,9).

At present, a number of minimally invasive techniques for epidural abscess drainage have been described in the literature, including the percutaneous computed tomography (CT)-guided needle aspiration and limited open drainage with epidural catheter irrigation⁽¹⁴⁾. However, few studies have described minimally invasive drainage under fluoroscopy and the outcomes of extensive SEA. Herein, we report a case of SEA extending over multiple spinal levels that was successfully evacuated using a fluoroscopically guided catheter through limited exposure to the spine.

CASE PRESENTATION

A 58-year-old man presented to our emergency department with acute back pain and a high-grade fever. Clinical examination revealed ASIA-C impairment in both lower extremities. On admission, the patient was presented with a very limited range of motion of the lumbar spine and diffuse tenderness on palpation of his back. Laboratory tests showed an increase in the white blood cell count (30,900 cells/mm³), with an erythrocyte sedimentation rate of 83 mm/h (normal value 0–15 mm/h) and a C-reactive protein (CRP) level of 122 mg/dL (normal value 0–5 mg/dL). Plain radiographs of the lumbar spine showed vertebral endplate destruction at L2/3 and L5/S1 (Fig 1A). The patient clinically deteriorated over the next 6 h after admission to the spinal surgery division and showed a fever of 38 °C and progressive flaccid paraparesis. A whole-spine magnetic resonance imaging (MRI) was performed, which showed spondylodiscitis at L2/3 and L5/S1 with an epidural abscess circumferential along L2-S1; this caused severe spinal canal stenosis with compromised cauda equina roots and posterior epidural abscess extending up to T6 and moderate spinal canal stenosis with spinal cord indentation (Fig 1B). There was a large rim-enhancing lesion along the left iliopsoas muscle.

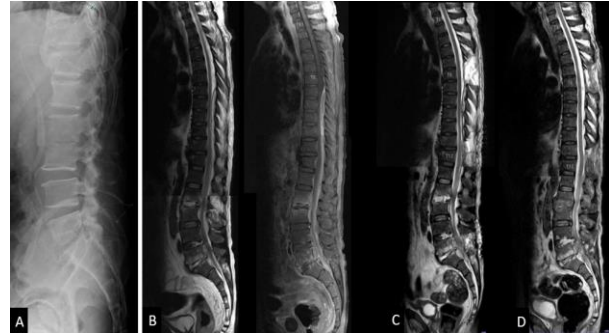


Fig. 1. (A) Plain radiographs of the lumbar spine showing vertebral endplates destruction of L2/3 and L5/S1 (B) Pre-operative sagittal T2W & T1W with gadolinium magnetic resonance image (C) Post-operative sagittal T2W magnetic resonance images at one week (D) Post-operative sagittal T2W magnetic resonance image at six weeks.

Operative procedure

General anesthesia was administered to the patient. The patient was placed in a prone position on a Jackson radiolucent table. The patient's back was prepped and draped from the thoracic spine area down to the gluteal cleft in a sterile manner. A fluoroscope was used to determine the site of midline skin incisions targeting T5-6, T11-12, and L5-S1. First, a longitudinal incision was made at the L5-S1 level. The paraspinal muscles were detached subperiosteally from the spinous process. Decompressive laminectomy was performed at L5 level. Yellowish pus was oozing from the epidural space; a pus specimen was obtained for culture. Laminectomies were performed in the same manner at T12 and T5. A 6 Fr open-ended barium impregnated ureteral catheter (Cook®, Bloomington, IN) was then inserted cranially into the posterior epidural space using Penfield No. 3 dissector. The catheter tip was advanced cranially under the lamina of L5 through T12, and then T12 through T5 under fluoroscopic guidance (Fig 2A, 2B). During catheter cannulation, the tip of the catheter was observed along the posterior epidural space to prevent dural sac penetration. Saline was used for "through and through" irrigation along the epidural space, and additional pus was aspirated through the catheter (Fig 2C, 2D). The adequacy of intra-operative decompression and drainage was observed when

the dura was expanded, and no residual fluid or pus collection was observed. A large left psoas abscess was percutaneously drained using a pigtail catheter under ultrasonographic and fluoroscopic guidance by an interventional radiologist.

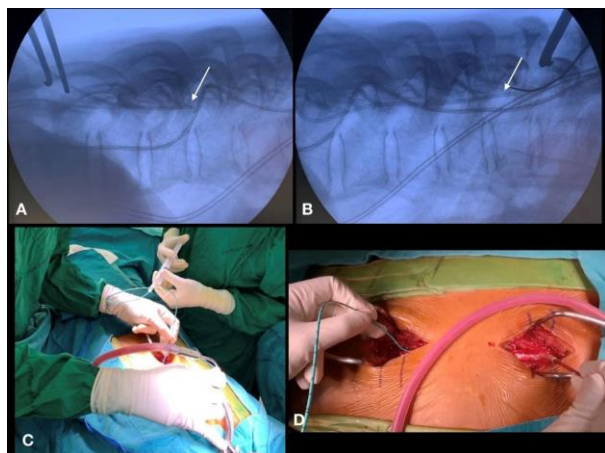


Fig. 2. (A, B) Intra-operative lateral fluoroscopic view of the thoracolumbar spine showing advancement of the radiopaque 6 Fr ureteral catheter tip in the epidural space up to T5-6 (arrows) (C, D) “Through-and-through” irrigation using saline along the epidural space and pus aspiration through the catheter

Post-operative course

A post-operative MRI showed resolution of the spinal canal stenosis (Fig 1C). The microbiological examination was positive for *Escherichia coli*. The patient received a six-week course of intravenous ceftazidime. Two weeks after surgery, the patient was voiding spontaneously, and his saddle anesthesia had completely resolved. Six weeks after surgery, neurological function improved to the ASIA-E scale, and repeated MRI showed no residual stenosis (Fig 1D). Laboratory tests showed a decrease in the white blood cell count (8,800 cells/mm³), with an erythrocyte sedimentation rate of 40 mm/h and a CRP level of 20 mg/dL.

DISCUSSION

In general, the preferred therapeutic approach for patients with SEA is a combination of antibiotics and urgent surgical decompression^(1,4). Patients with extensive SEA often have numerous

co-morbidities; severe thrombocytopenia or massive infection often worsens patient outcome⁽¹¹⁾. However, the ideal surgical management for this condition remains controversial. Two main surgical approaches have been described to evacuate an extensive SEA and to decompress the spinal cord; 1) wide decompression through multilevel laminectomy that may result in post-operative instability, late post-operative kyphosis, significant blood loss, and prolonged recovery time⁽¹²⁾, and 2) minimally invasive techniques such as limited decompression with catheter drainage and percutaneous CT-guided needle aspiration^(3,13,14). However, CT-guided aspiration can extend the infection to the subdural area by accidental penetration of the dura⁽⁷⁾. In this case, the extensive SEA was evacuated by skipped laminectomy and insertion of a fluoroscopically guided epidural catheter. Through and through irrigation was performed using a catheter from distal to proximal. The epidural space was irrigated until the proximal fluid egress became clear. Moreover, this technique reduced iatrogenic instability, post-operative pain, and blood loss. This is important in the management of SEA because it often affects patients with numerous co-morbidities⁽¹⁵⁾.

Various catheters for irrigation of the epidural space have been described, including the pediatric feeding tube, Fogarty catheter, and ventriculoperitoneal silicone shunt catheter^(7,16,17). The use of a pediatric nasogastric tube, which is small and flexible, results in its poor visualization on radiography. Concerns have been raised with the use of the Fogarty balloon because it may cause excessive hydraulic pressure in neural elements⁽¹⁷⁾. We used a 6 Fr radio-opaque ureteral catheter to evacuate the extensive SEA. The ureteral catheter allowed both irrigation and aspiration of the fluid component of the SEA. Although the ureteral catheter was too small to aspirate purulent discharge, it had superior rigidity compared to that of the pediatric feeding tube, making it easier to manually advance under fluoroscopic guidance in the posterior epidural space. This may provide an advantage when more distant pockets of epidural abscesses need to be drained. In some conditions, such as solidified abscess formation and adhesion

or abscess formation located anterior to the spinal cord, the use of ureteral catheter drainage is limited.

CONCLUSION

We recommend a limited approach to the spine with the use of a small radio-opaque ureteral catheter to effectively drain extensive SEA. This technique can be performed with less morbidity than open extensive surgical drainage. Fluoroscopy may help guide advancement of the catheter in the dorsal epidural space of the spinal column to achieve drainage of the SEA. Thus, this technique is safer and more effective than a blindly inserted epidural catheter. Nevertheless, the limitation of this minimal approach is direct visualization of the entire abscess.

CONFLICTS OF INTEREST

The authors have no conflicts of interest to declare.

REFERENCES

- Schwab JH, Shah AA. Spinal epidural abscess: diagnosis, management, and outcomes. *J Am Acad Orthop Surg* 2020;28:e929-23.
- Zimmerer SM, Conen A, Muller AA, et al. Spinal epidural abscess: etiology, predisponent factors and clinical outcomes in a 4-year prospective study. *Eur Spine J* 2011;20:2228-34.
- Lara-Reyna J, Yaeger KA, Margetis K. Transpedicular approach for ventral epidural abscess evacuation in the cervical spine. *World Neurosurg* 2021;145:127-33.
- Sharfman ZT, Gelfand Y, Shah P, et al. Spinal epidural abscess: a review of presentation, management, and medicolegal implications. *Asian Spine J* 2020;14:742-59.
- Darouiche RO. Spinal epidural abscess. *N Engl J Med* 2006;355:2012-20.
- Panagiotopoulos V, Konstantinou D, Solomou E, et al. Extended cervicolumbar spinal epidural abscess associated with paraparesis successfully decompressed using a minimally invasive technique. *Spine (Phila Pa 1976)* 2004;29:E300-3.
- Smith GA, Kochar AS, Manjila S, et al. Holospinal epidural abscess of the spinal axis: two illustrative cases with review of treatment strategies and surgical techniques. *Neurosurg Focus* 2014;37:E11.
- Andre V, Pot-Vaucel M, Cozic C, et al. Septic arthritis of the facet joint. *Med Mal Infect* 2015; 45:215-21.
- Muffoletto AJ, Ketonen LM, Mader JT, et al. Hematogenous pyogenic facet joint infection. *Spine (Phila Pa 1976)* 2001;26:1570-6.
- Du JY, Schell AJ, Kim C-Y, et al. 30-Day mortality following surgery for spinal epidural abscess: incidence, risk factors, predictive algorithm, and associated complications. *Spine (Phila Pa 1976)* 2019;44:E500-9.
- Sendi P, Bregenzer T, Zimmerli W. Spinal epidural abscess in clinical practice. *QJM* 2008; 101:1-12.
- Richmond B, Schmidt 3rd JH. Seventeen level laminectomy for extensive spinal epidural abscess: case report and review. *W V Med J* 1994; 90:468-71.
- Denis DJ, Champagne P-O, Hoffman H, et al. Catheter-based minimally invasive evacuation of extensive spinal epidural abscess: A technical report. *Cureus* 2019;11:e4649.
- Lyu R-K, Chen C-J, Tang L-M, et al. Spinal epidural abscess successfully treated with percutaneous, computed tomography-guided, needle aspiration and parenteral antibiotic therapy: case report and review of the literature. *Neurosurgery* 2002;51:509-12.
- Curry WT, Hoh BL, Amin-Hanjani S, et al. Spinal epidural abscess: clinical presentation, management, and outcome. *Surg Neurol* 2005; 63:364-71.
- Tahir MZ, Hassan RU, Enam SA. Management of an extensive spinal epidural abscess from C-1 to the sacrum. Case report. *J Neurosurg Spine* 2010;13:780-3.

17. Abd-El-Barr MM, Bi WL, Bahluyen B, et al. Extensive spinal epidural abscess treated with "apical laminectomies" and irrigation of the epidural space: report of 2 cases. *J Neurosurg Spine* 2015;22:318-23.