



## ***Serratia marcescens* Septic Arthritis and Osteomyelitis after COVID-19: A Case Report and Literature Review**

**Puthi Tantikosol, MD, Chavanont Sumanasrethakul, MD, Charoenchai Pakpianpairoj, MD**

*Institute of Orthopaedics, Lerdsin General Hospital, Bangkok, Thailand*

**Purpose:** Septic arthritis and osteomyelitis due to *Serratia marcescens* are very rare, with only a few cases reported in the literature. This report presents a case of septic arthritis and osteomyelitis of the hip joint caused by *Serratia marcescens* after COVID-19.

**Methods:** A case report of a patient who had septic arthritis of *Serratia marcescens* was reported. A review of literature of the bone and joint infection caused by *Serratia marcescens* was also done.

**Results:** The patient was successfully treated with an open arthrotomy, debridement, and intravenous antibiotics. After 9 months, the patient showed good functional outcomes, with no signs of recurrent infection.

**Conclusions:** Septic arthritis caused by *Serratia marcescens* is a rare condition. Early diagnosis and urgent surgical debridement are key factors for success.

**Keywords:** septic arthritis, osteomyelitis, *Serratia marcescens*, COVID-19

The COVID-19 pandemic, first reported in Wuhan, China, in December 2019, was defined as a global health crisis. This disease can cause various symptoms and severities, affecting many organs and systems in the body. Evidence shows that COVID-19 can cause “Long COVID-19 symptoms,” the sequelae of COVID-19, such as lung fibrosis, pulmonary emboli, cardiomyopathy, skin rash and arthralgia, sensory dysfunction, and stroke<sup>(1-2)</sup>.

*Serratia marcescens* is a gram-negative bacillus belonging to the Enterobacteriaceae family. This organism can cause septic shock, which has a high mortality rate. Diseases caused by *S. marcescens* in-

clude pneumonia, urinary tract infections, wound infections, meningitis, and endocarditis. To the best of our knowledge, there have been no reports of *S. marcescens* septic arthritis and osteomyelitis after COVID-19. The objective of this study was to report a case of septic arthritis and osteomyelitis caused by *S. marcescens*. The patient underwent an open arthrotomy and debridement. The patient had good functional outcomes, with no signs of recurrent infection at 9-month follow-up.

### **CASE REPORT**

A 54-year-old Thai female presented to our emergency department with right hip pain for 1 week. The underlying diseases were well-controlled hypertension and dyslipidemia. She was diagnosed with COVID-19 2 weeks before presentation and was treated by intravenous dexamethasone and favipiravir for 1 week. She denied any history of trauma. At the first visit, a physical examination revealed normal vital signs, with no

---

#### *Article history:*

*Received: August 3, 2022 Revised: October 17, 2022*

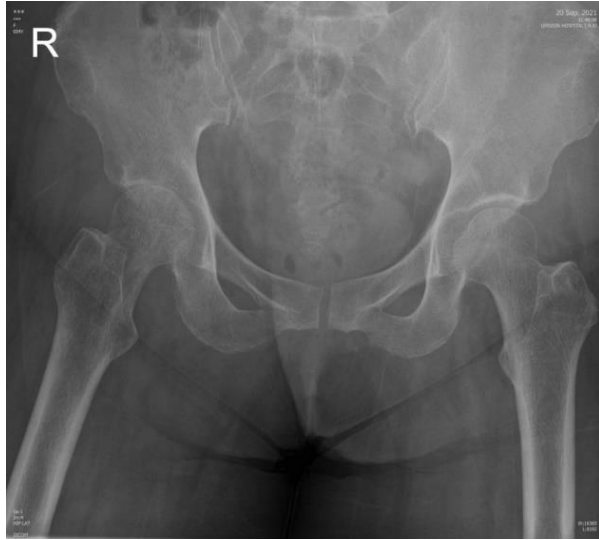
*Accepted: November 1, 2022*

*Correspondence to: Puthi Tantikosol, MD*

*Institute of Orthopaedics, Lerdsin General Hospital, Bangkok, Thailand*

*E-mail: puthi.tan@gmail.com*

fever. She had pain in the right hip with a limited range of motion. Plain radiography revealed narrowing joint space of the right hip, and no osteolytic lesions were seen (Figure 1). She was prescribed a painkiller and discharged from the hospital. The pain worsened 1 day after discharge, and she could not move or bear weight on the right hip, which was not relieved by the painkiller. She visited the hospital for reevaluation.



**Fig. 1.** Plain radiograph of the patient.

At the second visit, her blood pressure was 94/60 mmHg, tachycardia was 105 beats/min, and fever was 37.5°C. Blood tests showed an elevated C-reactive protein (CRP) level of 50 mg/L and an elevated erythrocyte sedimentation rate (ESR) level of 83 mm/h. She had leukocytosis, with a white blood cell count of 11,700 cells/ $\mu$ L with 80% neutrophils. Laboratory test results were negative for antinuclear antibodies, rheumatoid factor, anti-cyclic citrullinated peptide antibodies, hepatitis B virus surface antigen, anti-hepatitis C virus antibodies, and anti-human immunodeficiency virus antibodies. Magnetic resonance imaging of the right hip showed a narrowed joint space with bone erosion, bone marrow edema, soft tissue edema around the right hip, and fluid collection containing fat and gas bubbles. The patient was diagnosed with septic arthritis of the right hip. Open arthrotomy and debridement were performed with spinal analgesia. We used 10 L of fluid

irrigation solution, including saline, povidone-iodine, and hydrogen peroxide. Intraoperatively, we found pus around 5 ml and destruction of the hip joint and femoral head. The initial results of the intraoperative gram stain test were negative. Tissue and pus cultures were collected and sent for further analysis. The operative time was one hour. Pain improved immediately after the operation. Cefazolin was administered intravenously. All specimens of synovial fluid cultured in blood culture vials and tissue culture were positive for *S. marcescens*. Antimicrobial therapy was changed based on susceptibility data to intravenous ertapenem for 6 weeks. Oral ciprofloxacin was prescribed for 6 weeks after intravenous antibiotics.

After completing a 3-month course of intravenous antibiotics followed by oral antibiotics, the patient had only mild pain and could move her right hip, bear weight, and walk with gait assistance. CRP and ESR levels returned to normal. At the last follow-up, 9 months after the operation, she had no fever, pain, or signs of infection. She could walk and use the stairs independently. Both inflammatory markers were normal (ESR 18 mm/h; C-reactive protein level, 3 mg/L).

## DISCUSSION

*S. marcescens* is a gram-negative bacillus that can cause serious nosocomial infections, which are more common in severe cases as a cause of bacteremia, pneumonia, and urinary tract infections<sup>(3-5)</sup>. Primary joint infections with *S. marcescens* are rare. Almost all cases have occurred in trauma or drug addiction in critically ill patients<sup>(4-8)</sup>. In septic arthritis, gram-negative bacteria are associated with a poor prognosis. Previous studies have stated that septic arthritis caused by gram-negative bacteria requires a longer treatment duration because the response rate is lower and recurrent infection is more common<sup>(9-10)</sup>.

*S. marcescens* rarely presents with septic arthritis or osteomyelitis. In this case, *S. marcescens* was identified as the etiological agent of septic arthritis following COVID-19. The patient's COVID-19 was treated with intravenous dexamethasone and antiviral medication. We believe steroid use may have increased the risk of infection

in this patient or may be due to the sequelae of COVID-19.

*S. marcescens* is commonly resistant to various antibiotics, including penicillin G, macrolides, clindamycin, ampicillin, amoxicillin, first-generation cephalosporins, cefuroxime, nitrofurantoin, colistin, and tetracyclines<sup>(11-12)</sup>. Therefore, starting treatment for *Serratia* infections with piperacillin-tazobactam, fluoroquinolone, or carbapenem is recommended, then switching to the appropriate antibiotics after the antibiogram results.

### LITERATURE REVIEW

Septic arthritis caused by *Serratia*, a gram-negative bacterium, is rare. A few authors have reported this. A PubMed search on July 11, 2022, using the keywords “*Serratia marcescens*” and “septic arthritis” yielded 41 articles. Twenty-two articles, including case reports, were included. Nakashima et al. reported epidemic *S. marcescens*

arthritis as an iatrogenic infection in 10 patients using contaminated benzalkonium chloride anti-septic agent<sup>(13)</sup>. Ross et al. found *S. marcescens* in four intravenous heroin addicts in 1975, one of the most common pathogens among drug addicts<sup>(14)</sup>. Martinez et al. reported an immuno-competent patient with no history of hospital admission or drug addiction<sup>(15)</sup>. Hadid et al. reported a case of severe osteomyelitis and septic arthritis of the ankle caused by *S. marcescens* in an immunocompetent patient<sup>(16)</sup>. The patient had uncontrolled diabetes mellitus and minor trauma. Olut et al. reported a case of a 43-year-old male patient with trauma and fractures of the right patella and right femoral condyle diagnosed with posttraumatic septic arthritis due to *S. marcescens*, which was isolated from the patient’s synovial fluid culture. Treatment consisted of debridement and intravenous ertapenem for 4 weeks. At 6-month follow-up, they reported a 30% restriction of motion in the joint despite treatment<sup>(17)</sup>. Izmir Dr. Behçet Uz Children’s

**Table 1** Review of literature.

Paper	Case	Affected joint	Source	Treatment
Lafuente Martinez et al. <sup>(15,18)</sup>	Male, 17 years old	Knee	Intraarticular injection	Amikacin
Watanakunakorn <sup>(8)</sup>	Female, 69 years old	Sternoclavicular	Subclavian catheter	Ceftizoxime + gentamycin
Svensson et al. <sup>(22)</sup>	Male, 46 years old Male, 40 years old	Hip, ankle	Diabetes + UTI postoperative infection	TMP-SMX + cefotaxime ceftazidime
Greene <sup>(23)</sup>	Male, 16 years old	Ankle	Foreign body remnants (splinter)	Cefotaxime
Nakashima et al. <sup>(13)</sup>	8 cases	Knee, shoulder	Epidemic due to contaminated benzalkonium chloride	-
Carmichael <sup>(24)</sup>	Male, 15 months old	Vertebra	Broviac catheterization	Ceftriaxone
Chiu and Wang <sup>(6)</sup>	Male, 34 years old	Knee	Traffic accident, contaminated wound	Trimethoprim and Sulfamethoxazole
Hadid et al. <sup>(16)</sup>	Male, 72 years old	Ankle	Minor trauma contaminated with soil	Ertapenem
Sandal et al. <sup>(18)</sup>	Male, 10 weeks old	Knee	Escobar syndrome	Meropenem
Shah et al. <sup>(19)</sup>	Male, 50 years old	Infective endocarditis	IVDU	Meropenem
Giulia Fazio et al. <sup>(20)</sup>	Female, 46 years old	Pulmonary	Cavitated metastasis, history of swimming	-
Erin L Simon <sup>(21)</sup>	Male, 29 years old	Sacroiliac joint	Previous bloodstream infection	Ceftriaxone, vancomycin
Makusha et al. <sup>(25)</sup>	Male, 89 years old	Endophthalmos	Urinary tract infection	-

Hospital reported septic arthritis of the knee caused by *S. marcescens* in a 10-week-old baby with Escobar syndrome<sup>(18)</sup>. Treatment consisted of intravenous meropenem. Shah et al. reported a rare presentation of infective endocarditis due to *Serratia marcescens*<sup>(19)</sup>. The patient had a rapid onset of complications, including joint infections, splenic abscesses, myositis, and septic arthritis, despite an initial benign presentation of pneumonia. They concluded that *S. marcescens* bacteremia in patients with risk factors should prompt further investigation with a thorough evaluation of the source of infection and immediate treatment. Fazio et al.<sup>(20)</sup> described cavitated pulmonary nodules in a female patient with breast cancer concerning pulmonary cavities, and the differential diagnosis included metastatic lung nodules, rheumatoid arthritis, Langerhans cell histiocytosis, mycotic infections, and septic emboli. Simon et al. reported a case of septic sacroiliitis caused by *S. marcescens*; the patient could not walk for 3 weeks and was treated with intravenous ceftriaxone and vancomycin<sup>(21)</sup>. Makusha et al. presented the case of an 89-year-old man with *S. marcescens* urosepsis with a multifocal end-organ infection on F-FDG PET/CT, including aortitis, splenic abscess, septic arthritis, thoracolumbar discitis-osteomyelitis, and culture-confirmed bilateral endogenous endophthalmitis. Summary if the literature review is shown in Table 1.

In our case, the patient was treated with intravenous ertapenem for 6 weeks based on the culture results after debridement, and open arthroscopy was performed. The important factor is to obtain pus or tissue cultures before administering intravenous antibiotics to avoid false negatives of the culture. Early diagnosis and urgent surgical debridement are key factors for success.

## REFERENCES

1. Agarwala SR, Vijayvargiya M, Pandey P. Avascular necrosis as a part of 'long COVID-19'. *BMJ Case Rep* 2021;14:e242101.
2. Hønge BL, Hermansen MF, Storgaard M. Reactive arthritis after COVID-19. *BMJ Case Rep* 2021;14:e241375.
3. Henry B, Plante-Jenkins C, Ostrowska K. An outbreak of *Serratia marcescens* associated with the anesthetic agent propofol. *Am J Infect Control* 2001;29:312-5.
4. Villarino ME, Jarvis WR, O'Hara C, et al. Epidemic of *Serratia marcescens* bacteremia in a cardiac intensive care unit. *J Clin Microbiol* 1989;27:2433-6.
5. Archibald LK, Corl A, Shah B, et al. *Serratia marcescens* outbreak associated with extrinsic contamination of 1% chlorxylenol soap. *Infect Control Hosp Epidemiol* 1997;18:704-9.
6. Chiu LQ, Wang W. A case of unusual Gram-negative bacilli septic arthritis in an immunocompetent patient. *Singapore Med J* 2013;54:e164-8.
7. Peterson TC, Pearson C, Zekaj M, et al. Septic arthritis in intravenous drug abusers: a historical comparison of habits and pathogens. *J Emerg Med* 2014;47:723-8.
8. Watanakunakorn C. *Serratia marcescens* osteomyelitis of the clavicle and sternoclavicular arthritis complicating infected indwelling subclavian vein catheter. *Am J Med* 1986;80:753-4.
9. Patti JM, Bremell T, Krajewska-Pietrasik D, et al. The *Staphylococcus aureus* collagen adhesin is a virulence determinant in experimental septic arthritis. *Infect Immun* 1994;62:152-61.
10. Bayer AS, Chow AW, Louie JS, et al. Gram-negative bacillary septic arthritis: clinical, radiographic, therapeutic, and prognostic features. *Semin Arthritis Rheum* 1977;7:123-32.
11. Stock I, Burak S, Sherwood KJ, et al. Natural antimicrobial susceptibilities of strains of 'unusual' *Serratia* species: *S. ficaria*, *S. fonticola*, *S. odorifera*, *S. plymuthica* and *S. rubidaea*. *J Antimicrob Chemother* 2003;51:865-85.
12. Stock I, Grueger T, Wiedemann B. Natural antibiotic susceptibility of strains of *Serratia marcescens* and the *S. liquefaciens* complex: *S. liquefaciens sensu stricto*, *S. proteamaculans*

- and *S. grimesii*. *Int J Antimicrob Agents* 2003;22: 35-47.
13. Nakashima AK, McCarthy MA, Martone WJ, et al. Epidemic septic arthritis caused by *Serratia marcescens* and associated with a benzalkonium chloride antiseptic. *J Clin Microbiol* 1987;25: 1014-8.
  14. Ross GN, Baraff LJ, Quismorio FP. *Serratia* arthritis in heroin users. *J Bone Joint Surg Am* 1975;57:1158-60.
  15. Lafuente Martinez D, Bonilla Velasco FA, Sampedro Alvarez J, et al. Septic arthritis caused by *Serratia marcescens*. *Arthritis Rheum* 1981; 24:567-8.
  16. Hadid H, Usman M, Thapa S. Severe osteomyelitis and septic arthritis due to *Serratia marcescens* in an immunocompetent patient. *Case Rep Infect Dis* 2015;2015:347652.
  17. Olut A, Tosun S, Ari A, et al. Posttraumatic septic arthritis due to *Serratia marcescens*: Case report and review of literature. *Mediterr J Infect Microb Antimicrob* 2017;6:13.
  18. Sandal ÖS, Sarı F, Ceylan G, et al. *Serratia marcescens* septic arthritis in a case of escobar syndrome. *J Pediatr Emerg Intensive Care Med* 2017;4:84-8.
  19. Shah K, Patel S, Rashid S, et al. A rare presentation of infective endocarditis due to *Serratia marcescens*. *Cureus* 2022;14:e22936.
  20. Fazio G, Galioto F, Ferlito A, et al. Cavitated pulmonary nodules in a female patient with breast cancer: Keep in mind *Serratia marcescens*' infections. *Respir Med Case Rep* 2021;33: 101441.
  21. Simon EL, Wainblat EG, Krizo JA, et al. Septic Sacroiliitis caused by *Serratia marcescens*. *Am J Emerg Med* 2020;38:2758.e5-2758.e8.
  22. Svensson O, Parment PA, Blomgren G. Orthopaedic infections by *Serratia marcescens*: a report of seven cases. *Scand J Infect Dis* 1987;19: 69-75.
  23. Greene WB. Unrecognized foreign body as a focus for delayed *Serratia marcescens* osteomyelitis and septic arthritis. Two case reports. *J Bone Joint Surg Am* 1989;71:754-7.
  24. Carmichael KD. Childhood septic arthritis following treatment of spondylodiskitis from *Serratia marcescens*. *Orthopedics* 2003;26:519-21.
  25. Makusha LP, Young CR, Agarwal DR, et al. Bilateral end-organ endophthalmitis in setting of *Serratia marcescens* urosepsis on 18F-FDG PET/CT. *Clin Nucl Med* 2020;45:e141-3.