



Comparative Study of Union Rate in Closed Humerus Shaft Fracture After Operative Fixation with Anteromedial Versus Anterolateral Surface Plating Using the Anterolateral Approach: A Randomized Controlled Study

Tana Rattanakitkoston, MD, Narongrit Lothaisong, MD, Naruepol Ruangsillapanan, MD

Department of Orthopedics, Maharat Nakhon Ratchasima Hospital, Nakhon Ratchasima, Thailand

Purpose: Plate osteosynthesis is considered the gold standard for treating humeral shaft fractures, and orthopedic surgeons widely use the anterolateral approach with anterolateral surface placement. However, surgeons may have difficulties with the non-smooth surface and proximity to the radial nerve during their use. To address this challenge, we propose introducing the anterolateral approach with anteromedial surface placement. This study aimed to compare the outcomes between anteromedial and anterolateral surface plating using the anterolateral approach.

Methods: This study included 74 patients who sustained a mid-shaft humerus fracture (AO 12) and underwent open reduction internal fixation between December 2020 and December 2022. Twelve patients were excluded based on the exclusion criteria. Among the remaining patients, 30 were randomized and allocated to surgery with anteromedial surface plating, while 32 patients were treated with anterolateral surface plating through an anterolateral approach. Postoperative clinical and radiographic results were recorded and analyzed.

Results: The union rate, blood loss, operative time, and complications were not significantly different between the two groups. All the patients healed radiographically except for two in the anterolateral surface plating group, who required reoperation. Although anteroposterior alignment was significantly better in the anteromedial surface plating group, it was not clinically significant.

Conclusions: Anteromedial plating demonstrated a commendable union rate, offered assured alignment, and presented itself as a secure option for addressing fractures of the humerus shaft.

Keywords: Humerus, Humerus shaft fracture, Anteromedial plating, Anterolateral plating, Anterolateral approach

Humeral shaft fractures represent approximately 1–3% of all fractures⁽¹⁾. Conservative treat-

ment remains the mainstay for isolated humeral shaft fractures, yielding generally favorable outcomes⁽²⁾. Nevertheless, non-surgical approaches are linked to certain morbidities and complications, including nonunion, which has been reported to be as high as 25% in some studies, malunion, and persistent radial nerve deficits⁽³⁾. Surgical treatment becomes necessary in specific circumstances, including open fractures, associated neurovascular injuries, floating elbow, pathologic fractures, and

Article history:

Received: March 13, 2024 Revised: May 21, 2024

Accepted: June 4, 2024

Correspondence to: Tana Rattanakitkoston, MD
Department of Orthopedics, Maharat Nakhon Ratchasima Hospital, Nakhon Ratchasima, Thailand
E-mail: thana.kr@cpird.in.th

instances where non-operative management has proven ineffective. Surgical options encompass plate osteosynthesis, intramedullary nailing, or external fixation. Plate fixation remains the preferred method for surgically managing humeral shaft fractures due to its superior biomechanical properties in resisting anti-torsional forces⁽⁴⁾. The anterolateral surface plating, employed through an anterolateral approach, is widely utilized. However, the consideration of anteromedial surface plating, a less commonly discussed alternative, for humeral shaft fracture management is relatively rare⁽⁵⁻⁸⁾.

The anteromedial surface plating method has demonstrated numerous advantages for managing humeral mid-shaft fractures. One notable benefit is the plate's noninterference with the radial nerve, with no requirement to anatomically prebend the plate due to the smooth, bony surface⁽⁹⁾.

This study primarily aimed to investigate the outcomes related to the union rate. The secondary objective was to assess operative time, blood loss, alignment, and complications associated with the fixation of humeral mid-shaft fractures. We compared the anteromedial and anterolateral surface plating methods using an anterolateral approach.

MATERIALS AND METHODS

Selection of Patients

This randomized controlled study included 74 patients who sustained a humerus shaft fracture and underwent open reduction and internal fixation in our institute between December 2020 and December 2022, following approval by our local ethics committee. The inclusion criteria were a closed mid-humeral shaft fracture (AO 12), patients aged 20–60 years, and those who underwent surgery within 2 weeks after the initial injury. The exclusion criteria were an open fracture, vascular injury, radial nerve injury, pathological fracture, and ipsilateral upper limb injury (Fig. 1).

Informed consent was obtained from all the patients before inclusion in the study. The procedure was randomized using sealed envelopes in blocks of four to select the techniques of fixation. The envelopes were opened before making any skin incisions. The anterolateral approach was employed for all patients, with anteromedial and anterolateral surface plating for 30 and 32 patients, respectively. A senior trauma surgical team conducted all procedures. Table 1 presents the demographic data of the patients.

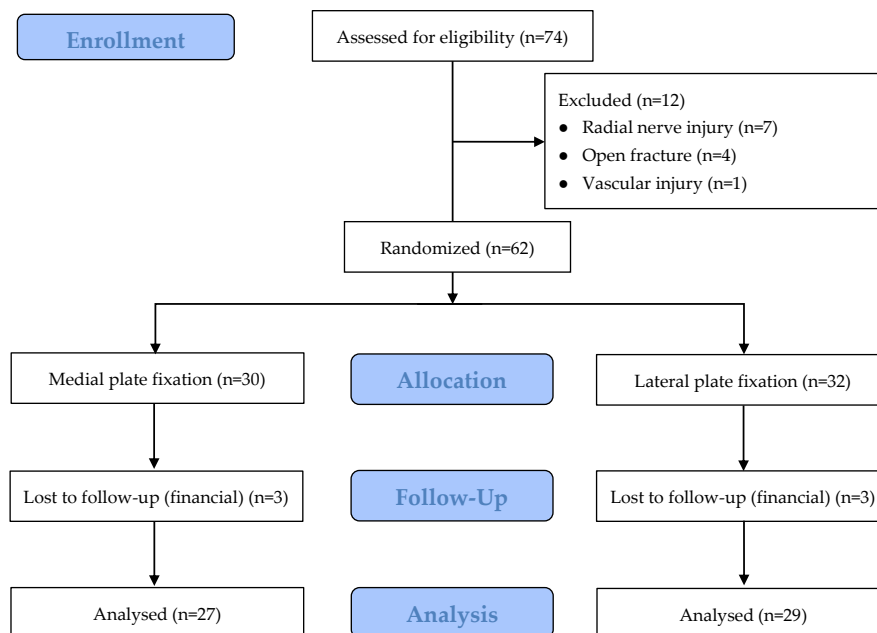


Fig. 1 CONSORT flow diagram.

Table 1 Baseline characteristics of the patients.

	Anteromedial plating group	Anterolateral plating group	p-value
Patient, n	30	32	
Gender, n (%)			
Male	19 (63.33)	24 (75.00)	0.319
Female	11 (36.67)	8 (25.00)	
Age, mean (SD)	38.93 (12.83)	35 (10.93)	0.198
Smoking status, n (%)	13 (43.33)	16 (50.00)	0.599
Mechanism of injury, n (%)			
Traffic accident	21 (70.00)	24 (75.00)	0.659
Fall from height	9 (30.00)	8 (25.00)	
Fracture type (AO/OTA Classification), n (%)			
Type A	10 (33.33)	15 (46.88)	0.419
Type B	19 (63.33)	15 (46.88)	
Type C	1 (3.33)	2 (6.25)	

Surgical Techniques

Anteromedial Surface Plating

Patients were placed in the supine position on a radiolucent table with the arm in abduction on an arm board after the induction of general anesthesia, and the entire limb was prepared, exposing the shoulder and elbow. The instruments used for all procedures consisted of a 4.5-mm narrow dynamic compression plate and a 4.5-mm cortical screw. The humerus was approached using the standard anterolateral technique (Fig. 2A)⁽¹⁰⁾. The incision was made along the lateral border of the biceps with sufficient length to allow insertion of the plate. The space between the biceps and brachialis was identified, and the musculocutaneous nerve was visualized and protected. The biceps muscle was retracted medially, and the brachialis muscle was split longitudinally to expose the humerus. Half of the brachialis was used as a cushion to protect the radial nerve on the lateral side, and we avoided placing the Hohmann retractor on the lateral side to reduce the risk of radial nerve injury. The fracture was then reduced, and the plate was applied to the anteromedial surface of the humerus, achieving temporary fixation with a bone reduction clamp (Fig. 2B). The arm was externally rotated to facilitate the visualization of the anteromedial surface of the humerus and to insert cortical screws for fixation (Fig. 2C). The

fractures were fixed using a compression plate in type A fractures. In contrast, the fractures were fixed with a bridging plate technique in type B and C fractures. Intraoperative fluoroscopy was used in cases of comminution where alignment and rotation were difficult to assess intraoperatively. The final steps included wound hemostasis, wound closure, and suction drain insertion. The surgery time, blood loss, and intraoperative complications were recorded. Plain anteroposterior (AP) and lateral humerus radiographs were obtained on the first postoperative day to analyze the quality of reduction (Fig. 2D).

Anterolateral Plating

We performed plate fixation through the anterolateral incision using the technique mentioned above; however, the plate fixation was applied to the anterolateral surface.

Postoperative Care and Follow-Up

A pouch arm sling was used, and the suction drain was removed 2 days postoperatively. The wound was inspected, and a sterile dressing was applied. A passive, assistive range of motion was encouraged from postoperative day 3 to avoid elbow and shoulder stiffness. Stitches were removed 2 weeks postoperatively.

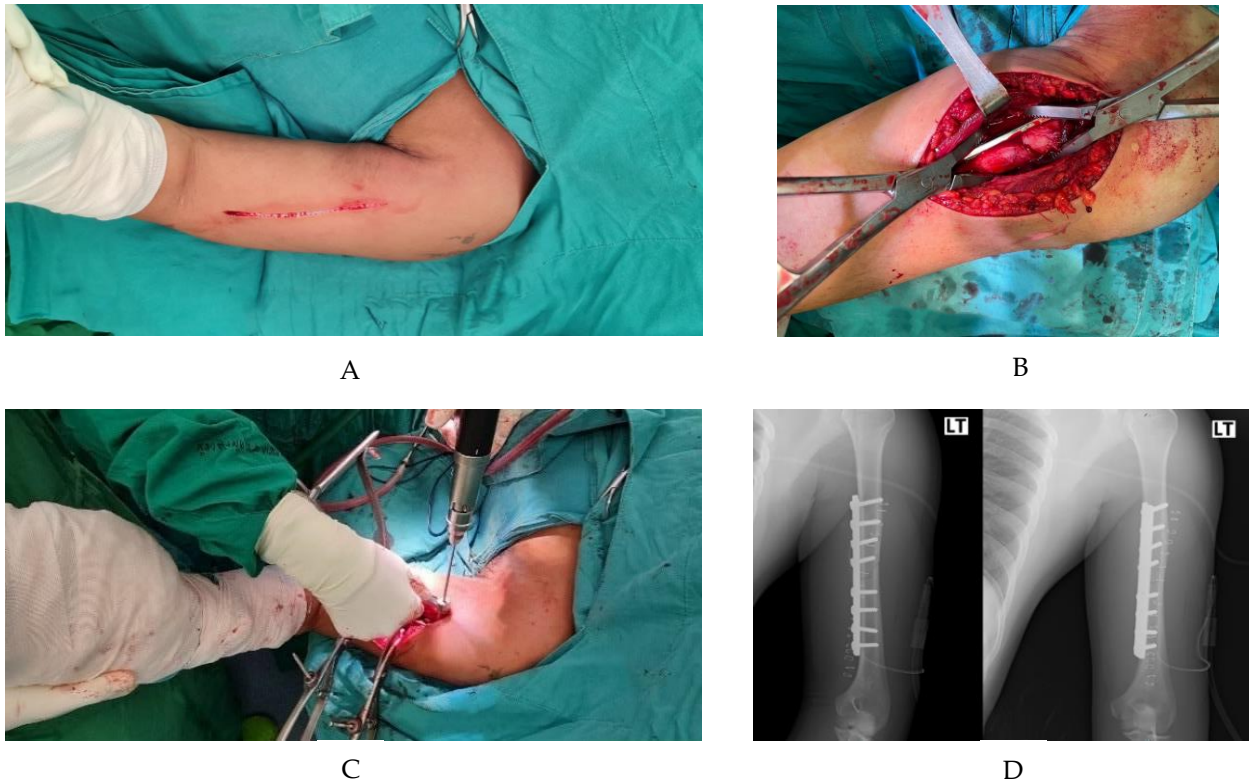


Fig. 2 A: Skin incision. B: Exposure of the anteromedial surface of the humerus and application of the plate to the bone. C: External rotation of the arm and cortical screw fixation performance. D: Postoperative radiograph.

Patients were followed up at 2 weeks, 6 weeks, 3 months, and 6 months postoperatively and until radiographic union was achieved. Follow-up included plain radiographs and clinical assessments, such as pain at rest and the ability to perform activities of daily living. The following methods were used to assess plain radiographic parameters.

The patient was positioned for the X-ray by well-trained orthopedic residents. The plain radiographs included the shoulder and elbow. A high-quality AP view was indicated by the visibility of the medial and lateral epicondyles in the distal humerus and the greater tuberosity on the lateral aspect of the proximal humerus. For the lateral view, the medial and lateral epicondyles were superimposed, and the scapula was in a lateral (Y-shaped) position. The assessment was performed by one well-trained orthopedic resident and one trauma orthopedic surgeon without blinding, as the assessors could see the plate position on the plain

radiographs. The radiographic parameters were recorded at the last follow-up or at the radiographic union, and the radiographic parameters are discussed below.

Union was characterized by the presence of bone bridging the fracture site across both cortices on radiographs taken in two planes, using established techniques for assessing tibial union, along with the clinical absence of pain and mobility at the fracture site⁽¹¹⁾. Achievement of the union was acknowledged when the specified criteria were met within the initial 26 weeks, while the delayed union was characterized by union occurring after the 26 weeks⁽¹²⁾.

AP angulation was measured on the AP view. The angle was measured by drawing a line along the axis of the humerus proximal to the fracture site and another line along the axis of the humerus distal to the fracture site. The angle between these lines represents the AP angulation.

Lateral angulation was measured similarly but along the lateral view of the fracture. One line was drawn along the axis of the humerus proximal to the fracture site, and another was drawn along the axis of the humerus distal to the fracture site. The angle between these lines represents the lateral angulation⁽¹³⁾.

Sample Size and Statistical Analysis

The sample size, calculated using a test comparing two independent means in Stata version 15.1 (StataCorp LP, College Station, Texas), was determined based on a similar study. The primary outcome, the union rate at 3 months, was 97% for the study group⁽¹⁴⁾ and 60% for the control group⁽¹⁵⁾. With a level of significance at 5% and power of 80%, the calculated sample size was 50. However, the total sample size became 60, allowing for a 20% loss to follow-up and dropout. Continuous variables, including age, time to union, operative times, blood loss, and alignment, were reported as mean and standard deviation or median and interquartile ranges. Categorical variables were presented as frequency and percentage. Differences in continuous data were assessed using Student's two-sample t-tests or the Wilcoxon rank sum test. Differences in categorical variables were evaluated through the chi-square test or Fisher exact test. A $p < 0.05$ was considered statistically significant. The reliability of measurements between two assessors was reported using a two-way mixed model intraclass correlation coefficient (ICC). The reliability was good, with

an ICC of 0.954 for AP angulation and 0.938 for lateral angulation.

RESULTS

This study enrolled 62 participants. Table 1 presents the demographic data for the two groups. Baseline characteristics, encompassing sex, age, smoking status, mechanism of injury, and fracture type, were comparable between both groups. The primary mechanism of injury in both groups was a traffic accident. The predominant fracture type was the AO Foundation/Orthopedic Trauma Association (AO/OTA) type B in the anteromedial plating group, and a mix of AO/OTA types A and B in the anterolateral plating group.

Three patients each were lost to follow-up in both groups due to financial problems. Thus, the analysis included 27 and 29 patients in the anteromedial and anterolateral plating groups, respectively. The data on union rate at the 3-month follow-up, time to radiographic union, operative time, blood loss, alignment, and complications in both groups are presented in Table 2. The union rate at the 3-month follow-up was 88.89% in the anteromedial plating group and 86.21% in the anterolateral plating group, with no statistically significant difference ($p=0.762$). The mean time to union in the anteromedial plating group was 13.54 weeks, whereas it was 12.75 weeks in the anterolateral plating group, with no statistically significant difference ($p=0.649$). Operative time was quite similar in both groups; however, the amount of

Table 2 Intraoperative and postoperative outcomes in both groups.

	Anteromedial plating group (N=27)	Anterolateral plating group (N=29)	p-value
Union at 3 months, n (%)	24 (88.89)	25 (86.21)	0.762
Union time (week)	13.54 ± 4.52	12.75 ± 7.78	0.649
Operative time (min)	79.19 ± 5.12	81.00 ± 6.16	0.822
Blood loss (mL)	146.67 ± 21.03	193.6 ± 23.55	0.145
Alignment (°)			
AP angulation	1.83 ± 0.53	3.42 ± 0.53	0.04
Lateral angulation	4.21 ± 0.84	3.10 ± 0.49	0.252
Complications			
Nonunion, n (%)	0	2 (6.90)	0.164

bleeding was slightly higher in the anterolateral plating group, although this difference was not statistically significant ($p=0.145$). AP angulation was significantly better in the anteromedial plating group, with a mean difference of 1.59° ($p=0.04$). However, this had little effect on the clinical and functional outcomes of the patients, and the alignment was acceptable in both groups.

Both groups had no radial palsy. In the anterolateral plating group, two patients experienced nonunion and required reoperation (Fig. 3). They underwent re-fixation using anterolateral plating and received iliac bone graft insertion, resulting in an uneventful union of the fractures.

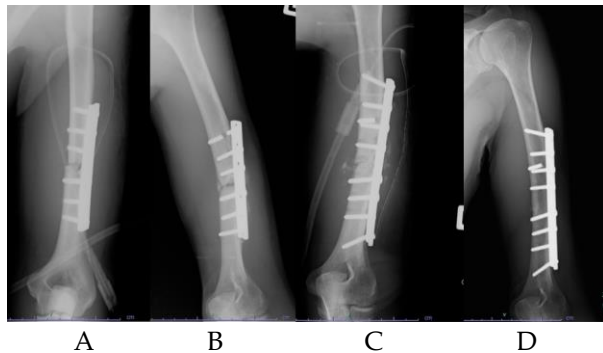


Fig. 3 A: Postoperative radiograph after fixation with anterolateral plating. B: Follow-up at 6 months showed nonunion of the fracture and loosening of screws. C: Revised fixation with longer anterolateral plating and an iliac bone graft. D: Follow-up at 6 months showed union of the fracture.

DISCUSSION

The gold standard technique for humeral shaft fracture treatment involves open reduction and fixation with a plate and screws, a well-established procedure⁽⁴⁾. Securing a strong fixation with the plate and screws is imperative for the early initiation of postoperative functional exercises and the restoration of limb function.

The cross-sectional shape of the humerus from the shaft to the distal metaphysis is triangular. It has three aspects: the surface, anteromedial, anterolateral, and posterior, where we can apply plate fixation^(16,17). Currently, anterolateral plating is the most widely used; however, it has some drawbacks. The lateral aspect of the humerus is

rough, leading to medial gapping during fixation. The plate often needs to be pre-contoured before placement. In contrast, the anteromedial surface is smoother, allowing the plate to be placed without pre-contouring.

For effective biomechanical considerations, it is recommended to position the plate on the tension side of the injury, allowing placement on the anterolateral or posterior areas of the bone⁽¹⁸⁾. In contrast to the femur or tibia, which primarily bear weight, the humerus experiences significant rotational forces, enabling placement of the plate on the medial aspect⁽¹⁹⁾. Some studies indicate that anteromedial plates exhibit mechanical properties similar to those of anterolateral and posterior plates, which implies that the fixation strength of anteromedial plates meets the mechanical requirements for humeral shaft fracture surgery⁽²⁰⁾.

Sanjay et al. performed medial plating through an anterolateral approach to stabilize humeral shaft fractures and found that the average operative time was 45 min, shorter compared to our study's 79 min; however, they reported an average blood loss of 200 mL, significantly more than our study's 147 mL. Callus was observed from 8 to 10 weeks. Within 3 months, patients had reintegrated their routine activities back into their lives⁽¹⁴⁾.

Rai et al. conducted a prospective observational study to compare anteromedial and anterolateral surface plating through an anterolateral approach in mid-shaft humeral shaft fractures. They discovered that anteromedial surface plating decreased fracture exposure time (24 min vs. 47 min, $p=0.05$) and blood loss in dissection (50 mL vs. 110 mL, $p=0.05$) significantly. Almost all patients (98.6%) achieved union at 12 months⁽⁹⁾.

The study by Kirin et al. demonstrated the advantages of anteromedial surface plating using an anterolateral approach over anterolateral surface plating in terms of reducing the incidence of iatrogenic radial nerve palsy and operative time. They observed no cases of iatrogenic radial nerve palsy when using anteromedial plating, whereas anterolateral plating resulted in 11.46% incidence. The mean operative time for anteromedial plating was significantly shorter compared to anterolateral plating (55.45 min vs. 74.61 min)⁽²¹⁾.

Recently, two randomized controlled studies compared anteromedial and anterolateral surface plating using the anterolateral approach. The first study, conducted by Gangwar et al., examined functional outcomes and union rates at 12 weeks. They found that functional outcomes, according to Rodriguez Merchan criteria, were good to excellent in 86.9% of the anteromedial surface plating group and 82.6% of the anterolateral surface plating group, with no statistically significant difference. The union rate at 12 weeks was 78.3%, with a mean union time of 11.7 ± 1.5 weeks for the anteromedial surface plating group, and 56.5% with a mean union time of 12.3 ± 1.8 weeks for the anterolateral surface plating group, with no statistically significant difference. The anterolateral approach used in this study differed between the two groups: in the anterolateral surface plating group, the brachialis muscle was split longitudinally to the bone, whereas in the anteromedial plating group, the biceps muscle was retracted medially, and the brachialis muscle was elevated from its medial margin, along with the musculocutaneous nerve⁽²²⁾.

The second study, conducted by Shodipo et al., examined iatrogenic radial nerve injury between the two groups. They found that iatrogenic radial nerve injury occurred in 9.3% of the anterolateral surface plating group compared with 4.8% of the anteromedial surface plating group, with no statistically significant difference⁽²³⁾.

In our study, we demonstrated no significant inter-group differences in union rate at the 3-month follow-up, time to union, operative time, blood loss, or complications. There was no radial nerve palsy in either group because our surgical technique uses the lateral half of the brachialis as a cushion to protect the radial nerve and avoids placing the Hohmann retractor on the lateral side. The advantage of anteromedial plating lies in its smooth surface, which slightly aids in improving AP alignment, as indicated in our study. However, the alignments after fixation in both groups are deemed acceptable.

Anteromedial plating offers benefits such as a simpler application of the plate on the smooth medial surface compared to the irregular anterolateral surface of the humerus, eliminates the need for

plate contouring and leads to improved AP alignment as shown in our study, results in no iatrogenic radial nerve palsy, and comparable outcome with anterolateral plating. However, when using anteromedial plating in comminuted fractures, some concerns should be considered. Before screw fixation, the arm needs to be externally rotated, which can cause rotational malalignment. Therefore, our recommendation is always to check rotation using fluoroscopy and assess the shoulder's range of motion after plate fixation.

The strength of our study is that it was a prospective randomized controlled trial comparing anteromedial and anterolateral surface plating regarding union rate, operative time, blood loss, alignment, and complications. Another strength is that the operations were performed by a single experienced trauma surgeon using the same approach and techniques. A limitation of our study is that we did not compare functional and clinical outcomes between the two groups. Further studies should include a larger population and compare functional and clinical outcomes between the groups.

CONCLUSIONS

This study offers valuable insights into the outcomes of anteromedial surface plating for humeral shaft fractures through an anterolateral approach, demonstrating acceptable union rates and overall satisfactory clinical results. This fixation technique can be employed safely and effectively for humeral shaft fractures.

REFERENCES

1. Ekholm R, Adami J, Tidermark J, et al. Fractures of the shaft of the humerus. An epidemiological study of 401 fractures. *J Bone Joint Surg Br* 2006;88:1469-73.
2. Sarmiento A, Kinman PB, Galvin EG, et al. Functional bracing of fractures of the shaft of the humerus. *J Bone Joint Surg Am* 1977;59:596-601.
3. Rämö L, Sumrein BO, Lepola V, et al. Effect of surgery vs functional bracing on functional

- outcome among patients with closed displaced humeral shaft fractures: The FISH randomized clinical trial. *JAMA* 2020;323:1792-801.
4. Orapiriyakul W, Apivatthakakul V, Theppariyapol B, et al. Humerus shaft fractures, approaches and management. *J Clin Orthop Trauma* 2023;43:102230.
 5. Blum J, Rommens PM. Surgical approaches to the humeral shaft. *Acta Chir Belg* 1997;97:237-43.
 6. Klenerman L. Fractures of the shaft of the humerus. *J Bone Joint Surg Br* 1966;48:105-11.
 7. Mulier T, Seligson D, Sioen W, et al. Operative treatment of humeral shaft fractures. *Acta Orthop Belg* 1997;63:170-7.
 8. Vander Griend R, Tomasin J, Ward EF. Open reduction and internal fixation of humeral shaft fractures. Results using AO plating techniques. *J Bone Joint Surg Am* 1986;68:430-3.
 9. Rai SK, Sud AD, Kashid M, et al. Anteromedial surface plating for midshaft fracture humerus through an anterolateral approach - A better option than anterolateral plating. *Malays Orthop J* 2020;14:66-72.
 10. Liskutin T, Summers H, Lack W, et al. Surgical technique: Anterolateral approach to the humerus. *J Orthop Trauma* 2018;32 Suppl 1:S6-S7.
 11. Whelan DB, Bhandari M, Stephen D, et al. Development of the radiographic union score for tibial fractures for the assessment of tibial fracture healing after intramedullary fixation. *J Trauma* 2010;68:629-32.
 12. Harkin FE, Large RJ. Humeral shaft fractures: union outcomes in a large cohort. *J Shoulder Elbow Surg* 2017;26:1881-8.
 13. Milner SA. A more accurate method of measurement of angulation after fractures of the tibia. *J Bone Joint Surg Br* 1997;79:972-4.
 14. Sanjay M, Raf M, Goud H, et al. Medial plating of humerus shaft fractures through anterolateral approach. *IOSR Journal of Dental and Medical Sciences* 2017;16:18-23.
 15. Vijayashankar M, Jayaprakash BA, Arumugam B. A prospective analysis of functional outcome of humeral diaphyseal fractures treated with dynamic compression plate. *International Journal of Contemporary Medical Research* 2016;3:2725-8.
 16. Qu X. Morphological effects of mechanical forces on the human humerus. *Br J Sports Med* 1992;26:51-3.
 17. Apivatthakakul T, Arpornchayanon O, Bavornratanavech S. Minimally invasive plate osteosynthesis (MIPO) of the humeral shaft fracture. Is it possible? A cadaveric study and preliminary report. *Injury* 2005;36:530-8.
 18. Müller ME. Treatment of nonunions by compression. *Clin Orthop Relat Res* 1965;43:83-92.
 19. Ambrósio J, Quental C, Pilarczyk B, et al. Multibody biomechanical models of the upper limb. *Procedia IUTAM* 2011;2:4-17.
 20. Zheng YF, Zhou JL, Wang XH, et al. Biomechanical study of the fixation strength of anteromedial plating for humeral shaft fractures. *Chin Med J (Engl)* 2016;129:1850-5.
 21. Kirin I, Jurišić D, Grebić D, et al. The advantages of humeral anteromedial plate osteosynthesis in the middle third shaft fractures. *Wien Klin Wochenschr* 2011;123:83-7.
 22. Gangwar V, Goel N, Dua A, et al. A comparison of anteromedial plating versus anterolateral plating for humerus shaft fractures using the anterolateral approach. *Cureus* 2024;16:e57235.
 23. Shodipo OM, Ibrahim SS, Ajiboye LO, et al. Anterolateral versus anteromedial plate osteosynthesis of midshaft humeral fractures; is there a difference in the rates of iatrogenic radial nerve palsy?. *Eur J Trauma Emerg Surg* 2024.