



Accuracy of Supra-acetabular Schanz Pin Insertion Using a Finger-Assisted Technique: A Cadaveric Study

Sofian Hayitahe, MD, Chulin Chewakidakarn, MD

Department of Orthopedic Surgery, Faculty of Medicine, Prince of Songkla University, Hatyai, Songkla, Thailand

Purpose: External pelvic fixation is an essential procedure for stabilizing unstable pelvic fractures. Supra-acetabular pin placement provides greater biomechanical stability than the supra-iliac crest technique, but it is technically more demanding and typically requires fluoroscopic guidance, which may be unavailable in urgent or resource-limited settings. In this study, we aimed to evaluate the accuracy of a finger-assisted technique for guiding supra-acetabular Schanz pin insertion without fluoroscopy.

Methods: This experimental cadaveric study included 18 fresh-frozen cadavers (36 hemipelves). Six orthopedic residents experienced in external pelvic fixation using sawbone models underwent training to perform the finger-assisted technique. Each resident performed the procedure on three cadaveric pelves (six hemipelves). After pin insertion, all the specimens were dissected using an iliofemoral approach. Pin position and complications, including hip joint penetration, lateral femoral cutaneous nerve injury, and intra-abdominal organ injury, were recorded.

Results: Of the 36 supra-acetabular Schanz pins inserted, 33 were completely intraosseous, yielding an accuracy rate of 91.7%. Three pins (8.3%) were malpositioned: two breached the medial cortex of the iliac wing, and one penetrated the hip joint. No visceral or lateral femoral cutaneous nerve injuries were observed.

Conclusions: Supra-acetabular external fixation using a finger-assisted technique is a useful alternative for guiding Schanz pin insertion, particularly in resource-limited settings.

Keywords: Supra-acetabular external fixation, Schanz pin, Accuracy of pin placement, Pelvic fracture

Patients with unstable pelvic fractures have high morbidity and mortality rates due to acute internal hemorrhage. Initial stabilization with an external pelvic fixator reduces blood loss by decreasing pelvic volume and enhancing the tam-

ponade effect. Both supra-iliac crest (high type) and supra-acetabular (low type) pin placement techniques have demonstrated clinical effectiveness⁽¹⁾.

Biomechanical studies have shown that the supra-acetabular corridor between the anterior inferior iliac spine (AIIS) and posterior superior iliac spine (PSIS) provides thicker cortical bone and greater stability than the supra-iliac crest region⁽²⁾. Furthermore, this technique significantly reduces morbidity and mortality in severe pelvic injuries, including APC II, APC III, LC II, and vertical shear fractures according to the Young-Burgess classification⁽³⁾.

Article history:

Received: September 8, 2025 Revised: February 23, 2026

Accepted: April 9, 2026

Correspondence to: Chulin Chewakidakarn, MD

Department of Orthopedic Surgery, Faculty of Medicine,
Prince of Songkla University, Hatyai, Songkla, Thailand

E-mail: Chulinccc@yahoo.com

The standard method of supra-acetabular external fixation uses C-arm fluoroscopic guidance to identify the entry point and determine the trajectory of Schanz pin insertion to achieve adequate stability and avoid complications such as lateral femoral cutaneous nerve injury, acetabular penetration, and pelvic floor violation⁽⁴⁾. In the meta-analysis by Stewart et al., the reported malposition rates were 4.3% for supra-iliac crest pin placement and 0.3% for supra-acetabular pin placement, suggesting that supra-acetabular pin placement is preferable for reducing redisplacement risk⁽⁵⁾. Furthermore, Gänsslen et al. reported a 4.5% incidence rate of lateral femoral cutaneous nerve injury associated with the standard supra-acetabular technique⁽⁶⁾.

Fluoroscopic guidance typically requires multiple views, including the obturator outlet view at the AIIS to identify the teardrop-shaped entry point, iliac oblique view to align the Schanz pin with the greater sciatic notch, and obturator inlet view to confirm proper pin placement within the safe corridor from the AIIS to the PSIS⁽⁷⁻⁹⁾. However, this process is time-consuming and technically demanding, and it may be impractical in emergency situations or in settings without access to a C-arm fluoroscope. Therefore, several alternative methods have been proposed.

In 1993, Noordeen et al. introduced a jig device consisting of inner and outer sleeves that allowed self-tapping pin insertion without predrilling. In their cadaveric study involving five hemipelves, all pins were accurately placed⁽¹⁾. In a later study, Haidukewych et al. evaluated the standard fluoroscopy-guided technique and reported only one misplaced pin among five cadavers⁽¹⁰⁾. Chana-Rodríguez et al. described an ultrasound-guided supra-acetabular pin placement technique and achieved excellent placement in all seven cadavers⁽¹¹⁾. Recently, Chumchuen et al. reported an open technique without fluoroscopy for supra-acetabular pin placement in a cadaveric study, showing accuracy and safety comparable to those of the standard fluoroscopy-guided percutaneous technique. Their results suggested that direct palpation of anatomical landmarks may allow reliable pin placement while reducing

operative time, particularly when fluoroscopic guidance is unavailable⁽¹²⁾.

Previous studies have primarily focused on supra-acetabular external fixation for stabilizing unstable pelvic fractures and explored alternative techniques or assistive devices to reduce operative time while maintaining accuracy. In this study, we propose a finger-assisted technique for guiding supra-acetabular Schanz pin insertion with the aim of minimizing operative setup requirements.

MATERIALS AND METHODS

This experimental study was conducted using 18 fresh-frozen cadavers, equivalent to 36 hemipelves, with approval from the institutional ethics committee. Six orthopedic residents with prior experience in external pelvic fixation using sawbone models underwent training to use the finger-assisted technique (Figure 1a). In this technique, the index finger was aligned along the bony corridor between the AIIS and PSIS (Figure 1b).

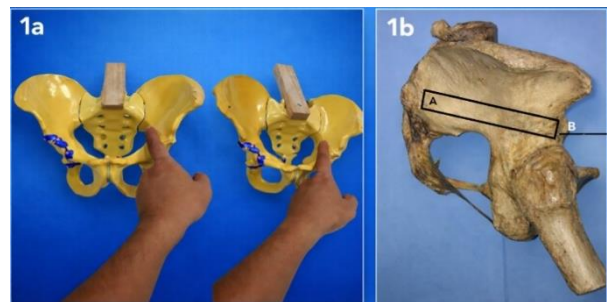


Fig. 1 a) Use the index finger to palpate the AIIS, then move toward the pelvic brim, and align it between the AIIS and PSIS. b) Corridor between the AIIS and PSIS. AIIS, anterior inferior iliac spine; PSIS, posterior superior iliac spine.

Each resident performed pin insertion in six hemipelves. After a standard incision, a 2–3 cm oblique skin incision was made approximately 4–6 cm distal and 3–4 cm medial to the anterior superior iliac spine (Figure 2). The AIIS was palpated, and a drill guide was positioned at its superior aspect. After the cortex was drilled with a 3.5-mm drill bit, the surgeon inserted an index finger into the pelvic brim to guide the pin direction. A 5 × 200-mm Schanz pin was advanced parallel to the guiding finger along the PSIS corridor (Figure 3). After pin

placement, the specimens were dissected using an iliofemoral approach. The iliac bone and hip joint were exposed to allow direct visualization of the pin position. Pin malposition and injuries to adjacent structures were recorded.

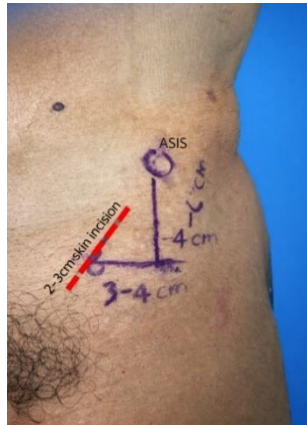

Fig. 2 A 2–3 cm oblique skin incision approximately 4–6 cm distal and 3–4 cm medial to the anterior superior iliac spine (ASIS).

RESULTS

In total, 36 hemipelves were evaluated in this study; 33 Schanz pins were completely intraosseous, resulting in an overall accuracy of 91.7%. Three pins were malpositioned: two breached the medial cortex of the iliac wing (Figure 4a), and one penetrated the hip joint (Figure 4b). No injuries to the visceral organs or lateral femoral cutaneous nerves were identified.

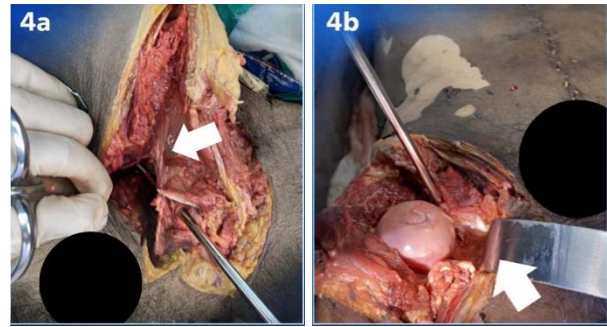


Fig. 4 a) Schanz pin breached the medial cortex of the iliac wing. **b)** Schanz pin penetrated the acetabulum.

DISCUSSION

Supra-acetabular external fixation is effective for stabilizing unstable pelvic fractures. Previous cadaveric studies using fluoroscopic guidance have reported a pin placement accuracy of approximately 90%⁽⁶⁾. In the present study, the finger-assisted technique achieved a comparable accuracy (91.7%) without fluoroscopic guidance (Tables 1-2).

All malpositioned pins were placed by junior residents (Tables 1-2), suggesting that operator experience influenced the accuracy. As the finger-assisted technique relies heavily on tactile anatomical guidance, adequate training may be crucial. The main limitation of this study was the use of intact cadavers, which do not replicate fracture-related pelvic deformities that may alter the safe corridor for pin placement.

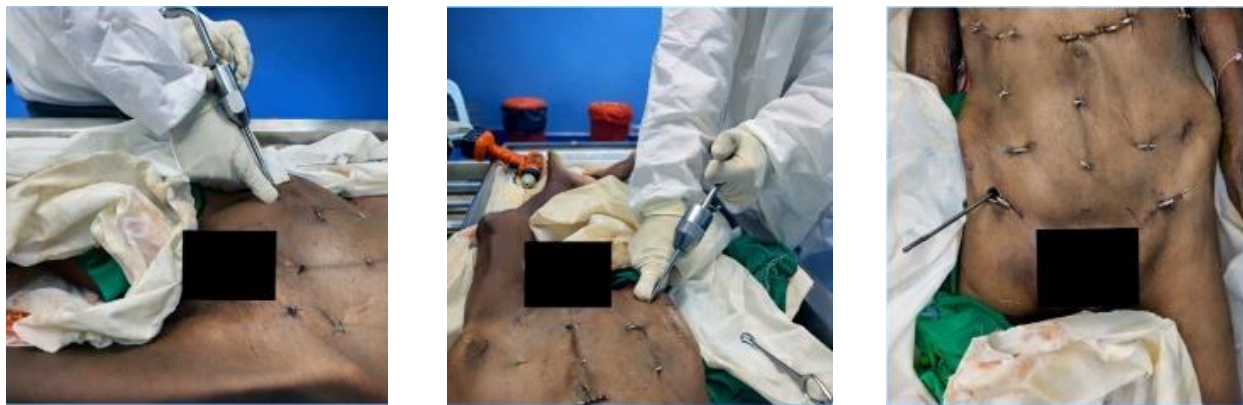

Fig. 3 The Schanz pin is inserted parallel to the guiding index finger along the posterior superior iliac spine (PSIS) corridor.

Table 1 Demographic characteristics of the cadavers.

Cadaver No.	Age (years)	Sex
1	57	male
2	66	male
3	81	male
4	76	male
5	78	male
6	59	female
7	83	female
8	68	female
9	35	male
10	65	male
11	66	male
12	75	female
13	64	male
14	72	male
15	38	male
16	47	male
17	68	female
18	80	female

Table 2 Study results.

Cadaver No.	Performer	Accuracy of Schanz pin placement in hemipelves	
		Right pelvis	Left pelvis
1	Performer 1 (senior)	Accurate	Accurate
2	Performer 1 (senior)	Accurate	Accurate
3	Performer 1 (senior)	Accurate	Accurate
4	Performer 2 (senior)	Accurate	Accurate
5	Performer 2 (senior)	Accurate	Accurate
6	Performer 2 (senior)	Accurate	Accurate
7	Performer 3 (senior)	Accurate	Accurate
8	Performer 3 (senior)	Accurate	Accurate
9	Performer 3 (senior)	Accurate	Accurate
10	Performer 4 (junior)	Accurate	Accurate
11	Performer 4 (junior)	Accurate	Accurate
12	Performer 4 (junior)	Misplaced	Accurate
13	Performer 5 (junior)	Accurate	Accurate
14	Performer 5 (junior)	Accurate	Accurate
15	Performer 5 (junior)	Accurate	Misplaced
16	Performer 6 (junior)	Misplaced	Accurate
17	Performer 7 (junior)	Accurate	Accurate
18	Performer 8 (junior)	Accurate	Accurate

CONCLUSIONS

The finger-assisted technique for supra-acetabular external fixation may be a useful alternative for Schanz pin insertion when performed by experience hands, particularly when imaging resources are limited. This technique may also be used as an adjunct to standard fluoroscopy-guided methods.

REFERENCES

1. Noordeen MH, Taylor BA, Briggs TW, et al. Pin placement in pelvic external fixation. *Injury* 1993;24:581-4.
2. Apostolov P. Methods and Techniques of Percutaneous External Fixation in Pelvic Fractures. *JofIMAB* 2011;17:166-71.
3. Gardner MJ, Nork SE. Stabilization of unstable pelvic fractures with supraacetabular compression external fixation. *J Orthop Trauma* 2007;21:269-73.
4. Lidder S, Heidari N, Gansslen A, et al. Radiological landmarks for the safe extracapsular placement of supra-acetabular half pins for external fixation. *Surg Radiol Anat* 2013;35:131-5.
5. Stewart RG, Hammer N, Kieser DC. External fixation of unstable pelvic fractures: a systematic review and meta-analysis. *ANZ J Surg* 2019;89:1022-7.
6. Gansslen A, Pohlemann T, Krettek C. [A simple supraacetabular external fixation for pelvic ring fractures]. *Oper Orthop Traumatol* 2005;17:296-312.
7. Calafi LA, Routt ML. Anterior pelvic external fixation: is there an optimal placement for the supra-acetabular pin? *Am J Orthop (Belle Mead NJ)* 2013;42:E125-7.
8. Guyton JL, Perez EA. Fractures of acetabulum and pelvis. In: Azar FM, Beaty JH, editor. Canale ST, editor. *Cambell's operative orthopedics*. 13th ed. Philadelphia, PA : Elsevie; 2017. p.2907.
9. Pelvic ring: reduction, and fixation-external fixation. AO Surgery Reference. <https://surgeryreference.aofoundation.org/orthopedic-trauma/adult-trauma/pelvic-ring/basic-technique/external-fixation>
10. Haidukewych GJ, Kumar S, Prpa B. Placement of half-pins for supra-acetabular external fixation: an anatomic study. *Clin Orthop Relat Res* 2003;(411):269-73.
11. Chana-Rodriguez F, Cuervas-Mons M, Rojo-Manaute J, et al. Ultrasound-guided supra-acetabular pin placement in pelvic external fixation: description of a surgical technique and results. *Injury* 2017;48 Suppl 6:S66- S74.
12. Chumchuen S, Lertpullpol W, Apivatgaroon A. Open technique for supra-acetabular pin placement in pelvic external fixation: a cadaveric study. *J Orthop Traumatol* 2022;23:14.