



Pediatric Tuberculous Osteomyelitis of the Hip Managed with an Antibiotic-Loaded Cement Spacer Fabricated Using a 3D-Printed Mold: A Case Report

Miguel Gabriel C. Ocampo, MD, Ralph August S. Manaois, MD, FPOA, Khristian S. Camagay, MD, Pocholo Iñigo B. Morales, MD, FPOA, Nike Kier P. Perez, MD, Mark Lawrence D. Gille, MD

Department of Orthopedics, Region 1 Medical Center, Dagupan City, Pangasinan, Philippines

Purpose: To describe a pediatric case of advanced tuberculous osteomyelitis of the hip managed with an antibiotic-loaded cement spacer fabricated using a three-dimensional (3D)-printed mold.

Methods: An 11-year-old child patient with a 2-year history of progressive hip pain, draining sinus formation, and inability to bear weight underwent staged surgical management, including debridement, sequestrectomy, and Girdlestone procedure. Radiographs demonstrated extensive proximal femoral osteolysis with superolateral displacement of the femoral head. Initial microbiologic studies were negative for *Mycobacterium tuberculosis*, while blood cultures grew *Burkholderia cepacia*. Histopathology later demonstrated caseating granulomatous inflammation consistent with tuberculosis. A patient-specific antibiotic-loaded cement spacer was fabricated using a 3D-printed mold based on contralateral hip measurements and implanted during the second-stage procedure.

Results: The patient initially showed clinical improvement, with reduced pain and decreased inflammatory markers. At 2 months, spacer displacement was noted, which was associated with poor functional outcomes (Harris Hip Score, 15.19). Long-term follow-up of the patient was not completed.

Conclusions: Customized spacer fabrication using 3D printing is feasible for pediatric patients with hip infections. However, outcomes may be limited in patients with advanced disease. Careful patient selection and follow-up are essential.

Keywords: Pediatric osteomyelitis, Tuberculous osteomyelitis, Hip joint, Antibiotic cement spacer, Three-dimensional printing

Tuberculous osteomyelitis of the hip in children is an uncommon but serious condition that often presents late and results in extensive bone destruction and functional impairment⁽⁸⁾. Manage-

ment of advanced disease often requires aggressive surgical intervention in addition to prolonged antimicrobial therapy^(3,7,10).

In severe cases, femoral head excision may be required to control infection, which presents challenges in managing dead space and delivering local antibiotic therapy^(2,9). Antibiotic-loaded cement spacers have been widely used in adult musculoskeletal infections to deliver local antimicrobial therapy while helping to maintain limb length and soft-tissue tension^(4,9). However, conventional hand-molded spacers are often

Article history:

Received: March 23, 2026 Revised: May 5, 2026

Accepted: May 19, 2026

Correspondence to: Miguel Gabriel C. Ocampo, MD

Department of Orthopedics, Region 1 Medical Center, Dagupan City, Pangasinan, Philippines

E-mail: migz938@gmail.com

anatomically imprecise and may contribute to instability.

Three-dimensional (3D) printing-assisted mold fabrication enables improved control of spacer geometry and customization^(1,12), particularly in cases with distorted anatomy. Although this technique has been described in adult populations, the literature on its application in pediatric cases of tuberculous osteomyelitis remains limited^(2,8).

This report describes the use of a customized antibiotic-loaded cement spacer fabricated using the 3D printing-assisted mold technique in a pediatric patient with advanced tuberculous osteomyelitis of the hip.

CASE REPORT

An 11-year-old child presented with a 2-year history of progressive right hip pain, a draining sinus, and progressive functional decline, eventually resulting in an inability to bear weight. Physical examination revealed a chronically ill,

undernourished child with a draining sinus over the proximal anterior thigh and markedly restricted hip range of motion (Fig 1A).

Laboratory studies revealed elevated inflammatory markers levels (erythrocyte sedimentation rate, 110 mm/h; C-reactive protein level, 74.26 mg/L). Radiographs showed osteolytic changes in the proximal femur with superolateral displacement of the femoral head (Fig 1B).

On admission, the patient underwent staged surgical management, including debridement, sequestrectomy, and femoral head excision (Girdlestone procedure) (Fig 1C). The second-stage procedure was performed 6 days after the initial operation. An antibiotic-loaded polymethyl methacrylate spacer impregnated with gentamicin was fabricated using a 3D-printed mold based on measurements of the contralateral hip. The spacer core was reinforced with stainless-steel rods and cerclage wires, and then implanted during the second-stage procedure (Figs 2A–C).

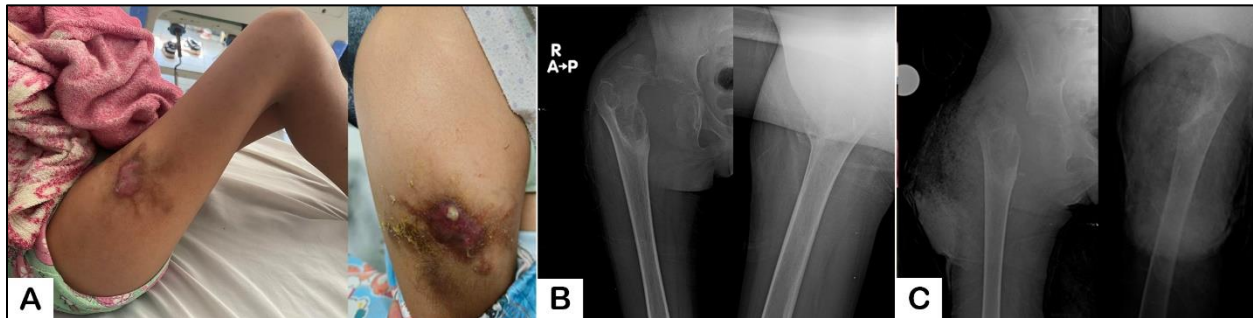


Fig. 1 Preoperative and immediate postoperative findings. (A) Clinical photographs demonstrating a draining sinus over the proximal anterior thigh with surrounding soft tissue inflammation. (B) Preoperative anteroposterior radiographs of the right hip showing osteolytic changes in the proximal femur with superolateral displacement of the femoral head. (C) Immediate postoperative radiograph following the Girdlestone procedure.

The intraoperative spacer placement and immediate postoperative radiographs are shown in Figs 2D–E. The immediate postoperative course was uneventful, with notable improvements in pain. Serial laboratory monitoring demonstrated a downward trend in inflammatory markers, including erythrocyte sedimentation rate and C-reactive protein level, following adjustment of antibiotic therapy based on culture results. White

blood cell counts also gradually normalized over the course of treatment.

The initial tuberculosis workup, including Xpert *Mycobacterium tuberculosis*/rifampicin resistance testing and acid-fast staining, yielded negative results. No organisms were isolated from local tissue specimens. However, blood cultures grew *Burkholderia cepacia*, and the patient was managed for chronic osteomyelitis with culture-

guided intravenous antibiotics in collaboration with pediatric infectious disease specialists. Histopathological examination of the debrided tissue demonstrated caseating granulomatous inflammation consistent with tuberculosis. Following histopathological confirmation, the patient was initiated on standard first-line anti-tuberculosis therapy (isoniazid, rifampicin, pyrazinamide, and ethambutol) with planned continuation-phase treatment per pediatric guidelines. The patient was subsequently discharged with instructions for outpatient follow-up, toe-touch weight-bearing,

and strict hip precautions, with weight-bearing progression guided by clinical and radiographic assessments.

Approximately two months postoperative, the patient returned with a persistent inability to bear weight. Radiographs demonstrated superior displacement of the spacer. Functional assessment revealed a poor outcome, with a Harris Hip Score of 15.19. The patient was subsequently lost to follow-up, precluding assessment of long-term outcomes.

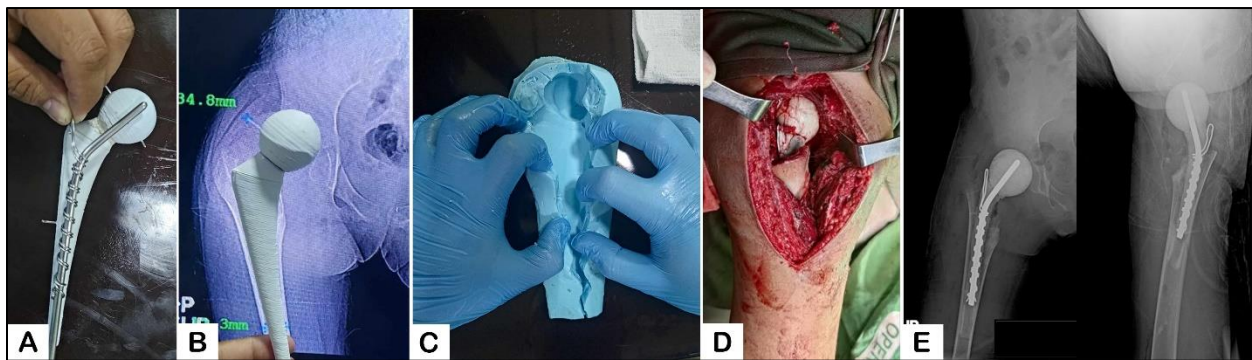


Fig. 2 Fabrication and implantation of the customized antibiotic-loaded cement spacer. (A) Spacer core reinforced with a stainless-steel rod and cerclage wires. (B) Preoperative radiographic templating using measurements from the contralateral hip to guide spacer sizing. (C) Silicone mold used for spacer fabrication. (D) Intraoperative image demonstrating placement of the customized spacer. (E) Immediate postoperative radiographs confirming spacer position.

DISCUSSION

Tuberculous osteomyelitis of the hip in children remains a clinical challenge because of its delayed presentation and extensive joint destruction⁽⁸⁾. Management of advanced disease often requires aggressive surgical intervention, including femoral head excision for infection control^(2,10).

Antibiotic-loaded cement spacers provide a local antimicrobial delivery and temporary structural support^(4,9). However, conventional techniques are limited by the variability in shape and size, particularly in pediatric patients^(2,5). 3D-printed mold fabrication offers improved customization and reproducibility^(1,12).

Previous studies have demonstrated favorable outcomes of antibiotic-loaded cement spacers in adults and periprosthetic infections^(4,12);

however, literature reporting similar evidence in pediatric populations remains limited⁽²⁾, particularly in cases of extensive bone destruction. In this case, spacer fabrication and implantation were technically successful; however, despite clinical improvement in the immediate postoperative period, the spacer was subsequently displaced, resulting in poor functional outcomes at short-term follow-up. This highlights the fact that technical feasibility does not necessarily translate into favorable outcomes for patients with advanced disease.

The spacer displacement was likely multifactorial, including extensive bone loss, inadequate acetabular containment following femoral head excision, and compromised soft-tissue support. Possibly, nonadherence to postoperative hip

precautions and weight-bearing restrictions by the patient may have further contributed to spacer instability. These findings underscore the importance of strict adherence to postoperative protocols and consideration of additional stabilization strategies in similar cases.

As a single case report, this study cannot establish effectiveness; however, it demonstrates the feasibility of this technique in a pediatric setting. Further studies with larger case series and standardized follow-up protocols are needed^(6,7,11).

CONCLUSIONS

This case demonstrates the technical feasibility of fabricating a 3D-printed mold for customized antibiotic-loaded cement spacers for pediatric tuberculous osteomyelitis of the hip. However, clinical outcomes may be limited in patients with advanced disease; therefore, careful consideration of patient factors and follow-up is essential.

REFERENCES

1. Ballard DH, Tappa K, Boyer CJ, et al. Antibiotics in 3D-printed implants, instruments and materials: benefits, challenges and future directions. *J 3D Print Med* 2019;3:83-93.
2. Canavese F, Corradin M, Khan A, et al. Successful treatment of chronic osteomyelitis in children with debridement, antibiotic-laden cement spacer and bone graft substitute. *Eur J Orthop Surg Traumatol* 2017;27:221-8.
3. Castellazzi L, Mantero M, Esposito S. Update on the management of pediatric acute osteomyelitis and septic arthritis. *Int J Mol Sci* 2016;17:855.
4. Chang CH, Hu CC, Chang Y, et al. Two-stage revision arthroplasty for Mycobacterium tuberculosis periprosthetic joint infection: an outcome analysis. *PLoS One* 2018;13:e0203585.
5. Chiappini E, Camposampiero C, Lazzeri S, et al. Epidemiology and management of acute haematogenous osteomyelitis in a tertiary paediatric center. *Int J Environ Res Public Health* 2017;14:477.
6. Jaramillo D, Dormans JP, Delgado J, et al. Hematogenous osteomyelitis in infants and children: imaging of a changing disease. *Radiology* 2017;283:629-43.
7. Le Saux N. Diagnosis and management of acute osteoarticular infections in children. *Paediatr Child Health* 2018;23:336-43.
8. Moon MS, Kim SS, Lee SR, et al. Tuberculosis of the hip in children: a retrospective analysis. *Indian J Orthop* 2012;46:191-9.
9. Paley D, Herzenberg JE. Intramedullary infections treated with antibiotic cement rods: preliminary results in nine cases. *J Orthop Trauma* 2002;16:723-9.
10. Saavedra-Lozano J, Falup-Pecurariu O, Faust SN, et al. Bone and joint infections. *Pediatr Infect Dis J* 2017;36:788-99.
11. Thakolkaran N, Shetty AK. Acute hematogenous osteomyelitis in children. *Ochsner J* 2019;19:116-22.
12. Zhang H, Zheng S, Liu Q, et al. 3D-printed antibiotic-loaded bone cement spacers as adjunctive therapy for hip periprosthetic infection after arthroplasty: a clinical assessment. *Int J Antimicrob Agents* 2024;63:107080.